

## Interpreting Acute Myocardial Infarction 40 Years Later. Evolution of Knowledge: What is the Best Explanation?

Vitor Coutinho Andrade,<sup>1</sup> Paulo Cury Rezende,<sup>1</sup> Whady Hueb,<sup>1</sup>  José Antonio Franchini Ramires<sup>1</sup>

Instituto do Coração do Hospital das Clínicas da Faculdade de Medicina da Universidade de São Paulo,<sup>1</sup> São Paulo, SP – Brazil

### Introduction

Plaque rupture and erosion are the most common immediate pathologies associated with acute myocardial infarction. However, other mechanisms must be considered. The reported case occurred at a time when percutaneous or pharmacological coronary revascularization were not the standard treatment, which sparked discussion about these other mechanisms, as well as the possible advantages associated with the myocardial revascularization procedures.

### Description

A 58-year-old man, previously asymptomatic and diagnosed with arterial hypertension and dyslipidemia, was evaluated in the emergency room (March 25, 1983) with severe retrosternal chest pain radiating to the left arm, accompanied by sweating and pallor, which had begun one hour before he arrived at the hospital. On presentation, vital signs were stable, and physical examination was unremarkable. The primary diagnosis was acute myocardial infarction (MI), supported by a 12-lead electrocardiogram (ECG) showing ST-segment elevation with subsequent formation of Q waves in precordial leads (Figure 1). Coronary angiography revealed a single-vessel pattern with subtotal occlusion of the left anterior descending artery and severe left ventricular dysfunction (Figure 1). Laboratory findings are presented in Table 1. Chest pain was relieved with intravenous nitroglycerin and analgesia with a morphine analog. Following a recovery period, the patient was discharged.

Three months later (July 14, 1983), the patient returned to the emergency department with anginal symptoms, but without sweating or pallor. On presentation, vital signs were again stable, and the physical examination was unchanged. The ECG showed recovery of the ST segment and only T wave inversion, along with the same angiographic characteristics as the initial examination (persistent single-vessel pattern with proximal sub occlusion of the left anterior descending

artery), except for ventriculography demonstrating recovery of ventricular function (Figure 1). The patient was discharged with outpatient follow-up, remaining asymptomatic for angina or signs of heart failure for years. In 1986, three years after the index event, a subsequent ambulatory ECG showed normalization, with the absence of Q waves in anterior leads, suggesting the absence of ventricular fibrosis in this region.

### Discussion

It is known that plaque rupture and erosion are the most common immediate pathologies associated with acute MI. However, other mechanisms must be considered:

#### A- Coronary artery spasm

MI due to spasm is underdiagnosed and refers to a sudden and intense vasoconstriction of an epicardial coronary artery that causes vessel occlusion or near occlusion that, if prolonged, can progress to irreversible myocardial injury. Proposed mechanisms include endothelial dysfunction and primary hyperreactivity of vascular smooth muscle cells. In the present case, the possibility of a coronary spasm mechanism should not be ignored.

#### B- Acute MI with “close/open” artery

Much evidence has confirmed atherosclerotic plaque fissuring followed by thrombus formation as the underlying pathologic process causing coronary artery occlusion resulting in acute MI. DeWood et al.<sup>1</sup> showed occlusive thrombus in 86 percent of the patients in angiography within 4 hours of the onset of acute MI and this proportion decreased significantly to 65 percent when patients were studied 12 to 24 hours after the onset of symptoms. Coronary occlusion results in myocardial ischemia, leading to ventricular dysfunction and myocardial necrosis. Spontaneous restoration of antegrade flow during this early period of acute MI can arrest the progression of myocardial cell death and salvage function in jeopardized myocardium. In this case, spontaneous and early lysis of the thrombus seems to be an attractive possibility.

#### C- Spontaneous thrombolysis and reperfusion

In a pioneering procedure, Galiano et al.<sup>2</sup> performed mechanical reperfusion in the acute phase of MI. After identifying a thrombus in the right coronary artery of a patient with cardiogenic shock, the interventional cardiologist “fractured” the occlusive thrombus, providing reperfusion and reversing the cardiogenic shock. During the angiography performed in the acute phase of the myocardium, no intraluminal thrombus was observed. However, the occurrence of spontaneous thrombolysis and reperfusion seems to be

### Keywords

Myocardial Infarction; Myocardial Stunning; Coronary Vasoospasm; Dyslipidemias; Diagnostic, Imaging/methods

#### Mailing Address: Whady Hueb •

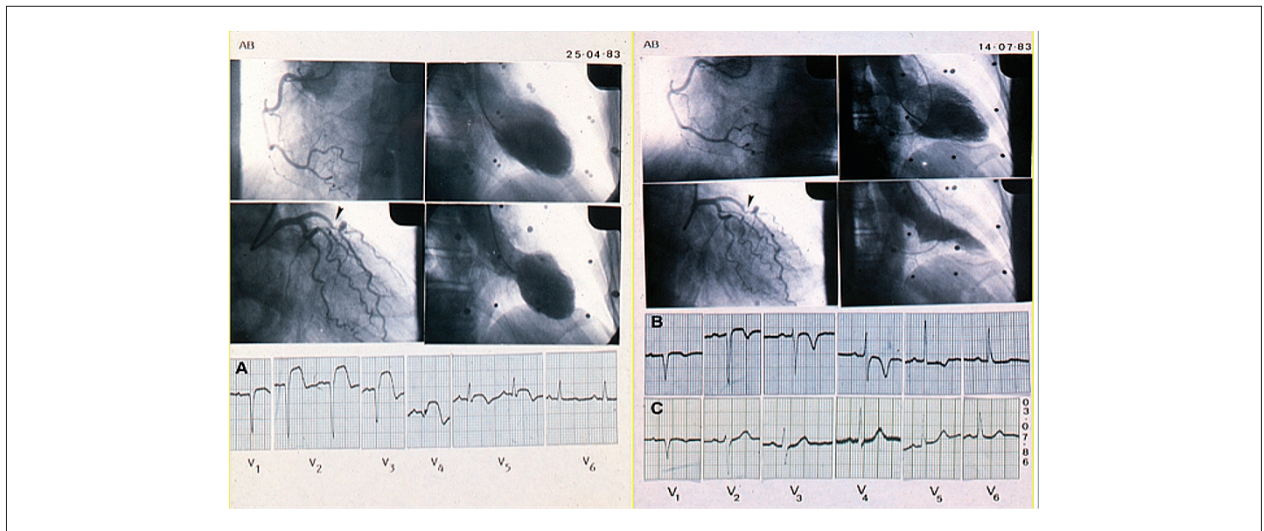
Instituto do Coração do Hospital das Clínicas da Faculdade de Medicina da Universidade de São Paulo – Av. Dr. Eneas Carvalho Aguiar, 44 AB Bl 1 Sala 114. Postal Code 05403-000, São Paulo, SP – Brazil

E-mail: whady.hueb@incor.usp.br

Manuscript July 12, 2023, revised manuscript November 01, 2023, accepted January 18, 2024

Editor responsible for the review: Gláucia Maria Moraes de Oliveira

DOI: <https://doi.org/10.36660/abc.2023-0757i>



**Figure 1** – Immediate and late coronary cineangiography and ECG images. CAPTION: Upper left frame: Sub occlusion of the anterior descending artery. Circumflex and right coronary arteries: absence of obstructions. Left ventricle: severe systolic dysfunction. Upper right frame (three months later). Similar angiogram with recovery of the left ventricle function. ECG (A): ST-segment elevation in precordial leads. ECG (B): ST-segment recovery and T wave inversion only. ECG (C): Three years later: Close to normal.

a rational model of complete coronary occlusion quickly relieved by intrinsic thrombolytic mechanisms, which can be difficult to diagnose by angiography but cannot be ruled out.

#### D- Takotsubo Syndrome

Stress cardiomyopathy occurs in approximately 1 to 2 percent of patients presenting with ST-elevation MI.<sup>3</sup> The pathogenesis of this disorder is not well understood. Several features of stress cardiomyopathy suggest that this disorder may be caused by diffuse catecholamine-induced microvascular spasm or dysfunction, resulting in myocardial stunning,<sup>4</sup> or by direct catecholamine-associated myocardial toxicity.<sup>5</sup> Support for a possible pathogenic role for catecholamines comes from studies in which plasma catecholamines were measured at presentation.<sup>6</sup> In the present case, the possibility of Takotsubo cardiomyopathy could also not be ruled out, although less likely after the angiographic evidence of obstructive coronary artery disease.

#### E- Stunning Myocardium

Myocardial stunning was established in the pioneering experiments of Heyndrickx et al.<sup>7</sup>, who demonstrated in a canine model that brief coronary occlusion was followed by sustained regional post-ischemic contractile dysfunction that fully recovered after hours, with this recovery being slower in those exposed to longer ischemia time.

So, the understanding of the stunned myocardium is characterized by a disproportionately long-lasting (hours to days), yet reversible, contractile dysfunction that follows a brief bout of myocardial ischemia when coronary blood flow is fully restored, compatible with the ventricular recovery evidenced in this case.

#### Final message

The reported case occurred at a time when percutaneous coronary revascularization was not the standard treatment for acute coronary syndrome. It was only in 1986, with the publication of the GISSI<sup>8</sup> study, that the era of chemical reperfusion began. Thus, ventricular function recovery

**Table 1** – Laboratory characteristics on admission

<b>Hemoglobin</b>	14 g/dL
<b>Hematocrit</b>	43%
<b>White cells count</b>	6.510 mm <sup>3</sup>
<b>Sodium</b>	142 mEq/L
<b>Potassium</b>	4.1 mEq/L
<b>Urea</b>	41 mg/dL
<b>Creatinine</b>	0.9mg/dL
<b>C reactive protein</b>	<5 mg/L
<b>CK-MB (peak)</b>	988 U/L
<b>Arterial blood gas</b>	
pH	6,98
pCO <sub>2</sub>	16.02 mmHg
pO <sub>2</sub>	21.70 mmHg
HCO <sub>3</sub>	27.8 mEq/L
Base excess	-7.5 mEq/L
Lactate	2.7 mg/dL

occurred despite coronary flow limitation caused by artery subocclusion. Presently, ventricular recovery observed in this case would likely be attributed to coronary flow restoration intervention; however, this reasoning is not always accurate. Additionally, when observing a subocclusive coronary plaque, we must always question the occurrence of adjunct non-atherosclerotic mechanisms for acute coronary syndrome. As demonstrated above, despite several possible pathophysiological mechanisms, defining it is not always an easy task.

### Acknowledgements

The support for the present study was provided in part by the Zerbini Foundation, São Paulo, Brazil. The authors are solely responsible for the design and conduct of this study, all study analyses, the drafting and editing of the paper, and its final contents.

### Author Contributions

Conception and design of the research: Andrade VC; Acquisition of data and Analysis and interpretation of the

data: Hueb W; Writing of the manuscript: Andrade VC, Rezende PC; Critical revision of the manuscript for important intellectual content: Rezende PC, Hueb W, Ramires JAF.

### Potential conflict of interest

No potential conflict of interest relevant to this article was reported.

### Sources of funding

There were no external funding sources for this study.

### Study association

This study is not associated with any thesis or dissertation work.

### Ethics approval and consent to participate

This article does not contain any studies with human participants or animals performed by any of the authors.

### References

1. DeWood MA, Spores J, Notske R, Mouser LT, Burroughs R, Golden MS, et al. Prevalence of total coronary occlusion during the early hours of transmural myocardial infarction. *N Engl J Med*. 1980;303(16):897-902. doi: 10.1056/NEJM198010163031601
2. Galiano N, Macruz R, Arie S, Armelin E, Frack C, Pileggi F, et al. Myocardial infarction and shock. Treatment by arterial recanalization through cardiac catheterism. *Arq Bras Cardiol*. 25(2):197-204.
3. Kurowski V, Kaiser A, von Hof K, Killermann DP, Mayer B, Hartmann F, et al. Apical and midventricular transient left ventricular dysfunction syndrome (tako-tsubo cardiomyopathy): frequency, mechanisms, and prognosis. *Chest*. 2007;132(8):809-16. doi: 10.1378/chest.07-0608
4. Gianni M, Dentali F, Grandi AM, Sumner G, Hiralal R, Lonn E. Apical ballooning syndrome or takotsubo cardiomyopathy: a systematic review. *Eur Heart J*. 2006;27(13):1523-9. doi: 10.1093/eurheartj/ehl032
5. Nef HM, Mollmann H, Kostin S, Troidl C, Voss S, Weber M, et al. Tako-Tsubo cardiomyopathy: intraindividual structural analysis in the acute phase and after functional recovery. *Eur Heart J*. 2007;28(20):2456-64. doi: 10.1093/eurheartj/ehl570
6. Wittstein IS, Thiemann DR, Lima JA, Baughman KL, Schulman SP, Gerstenblith G, et al. Neurohumoral features of myocardial stunning due to sudden emotional stress. *N Engl J Med*. 2005;352(6):539-48. doi: 10.1056/NEJMoa043046
7. Heyndrickx GR, Millard RW, McRitchie RJ, Maroko PR, Vatner SF. Regional myocardial functional and electrophysiological alterations after brief coronary artery occlusion in conscious dogs. *J Clin Invest*. 1975;56(4):978-85. doi: 10.1172/JCI108178
8. Gruppo Italiano per lo Studio della Streptochinasi nell'Infarto Miocardico (GISSI). Effectiveness of intravenous thrombolytic treatment in acute myocardial infarction. *Lancet*. 1986;1(8478):397-402. PMID: 2868337



This is an open-access article distributed under the terms of the Creative Commons Attribution License