

COMPARATIVE STUDY OF JEJUNAL AND COLONIC ALTERATIONS BETWEEN GASTROJEJUNODUODENAL AND GASTROCOLODUODENAL INTERPOSITION IN DOGS

Estudo comparativo das alterações jejunais e colônicas com a interposição gastrojejunoduodenal e gastrocoloduodenal em cães

Marilles **PORTO MATTOS**, Alcino **LÁZARO DA SILVA**

From the Departamento de Cirurgia da Faculdade de Medicina da Universidade Federal de Minas Gerais, Belo Horizonte, MG, Brazil

ABSTRACT – Background - The intestinal interpositions are important in various operations of the digestive tract. However, they are capable to produce serious immediate and late complications. **Aim** - To compare clinical and surgical outcomes, as well as intestinal pathological findings, in dogs submitted to jejunum and colon interposition. **Methods** - Forty male mongrel dogs were immunized and dewormed, between 36 and 72 months old and weighting from 6 to 16 kg divided into two groups of 20 (G1=gastrojejunoduodenal and G2=gastrocoloduodenal). They were anesthetized and submitted to laparotomy with jejunum and colon interposition between the gastric antrum and the duodenum. On the 120th postoperative day, a relaparotomy was performed with removal of the jejunum/colon segments for evaluation. The segments were processed using Bouin and tissue were stained with H&E for histological analysis. Clinical and surgical outcomes analyzed were weight, diarrhea, fistula, infection, suture dehiscence and incisional hernia. The pathological analysis involved neutrophilic infiltration, increase in number of goblet cells and villous and crypts hypotrophy. Mann-Whitney and Fisher Exact tests were used for groups comparisons. **Results** - Dogs that underwent gastrocoloduodenal interposition had a higher weight loss ($p<0.05$) and more diarrhea ($p<0.001$). Clinically, controlled fistula rates were 20% in G1 and 100% in G2. Complications occurred in 20% in G1 and in all animals in G2 ($p<0.001$). Pathological alterations were also more prevalent in G2 ($p<0.001$). **Conclusion** - There is a high morbidity and complication rates involving intestine interposition and higher in G2 where colon segments were used.

HEADINGS - Anastomosis. Interposition. Jejunum. Colon. Dogs.

Correspondence:

Alcino Lázaro da Silva
Rua Guaratinga, nº15, Sion, CEP 30.315-430,
Belo Horizonte, MG, Brasil

Financial source: none
Conflicts of interest: none

Received for publication: 28/03/2013
Accepted for publication: 19/06/2013

DESCRITORES - Anastomose. Interposição. Jejunum. Colo. Cães.

RESUMO - Racional - As interposições intestinais são importantes em diversas operações do tubo digestivo. Contudo, são passíveis de complicações imediatas e tardias. **Objetivo** - Comparar as interposições com segmentos de jejuno e de colo em cães, quanto à evolução clínica e cirúrgica e aspecto anatomopatológico dos segmentos interpostos. **Métodos** - Foram utilizados 40 cães sem raça definida, imunizados e vermifugados, machos, idade entre 36 e 72 meses, peso entre 6 e 16 kg distribuídos em dois grupos de 20 (G1=gastrojejunoduodenal e G2=gastrocoloduodenal). Submeteram-se à laparotomia para interposição de jejuno e de colo entre o antro gástrico e o duodeno. Após 120 dias, foi realizada relaparotomia para remoção dos segmentos de jejuno e de colo e analisados pelo método Bouin e cortes histológicos corados por H&E para estudo anatomopatológico. Os resultados clínicos e cirúrgicos analisados foram peso, diarreia, fístulas, infecção, deiscência de sutura e hérnia incisional. A análise patológica envolveu infiltração de neutrófilos, aumento do número de células calciformes e das vilosidades e hipotrofia de criptas. Os testes de Mann-Whitney e Exato de Fisher foram utilizados na comparação entre os grupos. **Resultados** - Os cães submetidos à interposição gastrocoloduodenal produziram mais perda de peso ($p<0,05$) e diarreia ($p<0,001$). A taxa de fístula clínica foi de 20% no G1 e 100% no G2. Infecção, deiscência e hérnia incisional ocorreram em 20% do grupo G1 e em todo grupo G2 ($p<0,001$). Quanto às alterações histopatológicas também foram intensas no G2 ($p<0,001$). **Conclusão** - A morbidade associada à interposição com segmento de intestino é alta e foi maior no grupo com interposição de segmento colônico.

INTRODUCTION

METHOD

Many diseases require interposition of an intestinal segment in order to improve, replace or create absent or defunctionalized organs.^{1, 2, 7, 11, 13, 14, 15, 16, 21, 24, 25}

The problems that interposition has increasingly presented are overcome by early monitoring of those who will undergo the operation. However, the satisfaction of patients undergoing repair, replacement or creation of an organ with the use of improved techniques using modified functional fabric, is varied. The search continues for an adequate substitute.^{27, 28}

Interest in the study of intestinal interposition is increasing and studies have been presented in several papers. Experiments confirm that transplantation of a segment of the digestive tract to the mesenteric pedicle is feasible. Studies in animals show that mucosal atrophy may occur when exposed to the environment, such as in ileostomies and celiac disease, but do not progress to metaplasia or dysplasia.^{2, 4, 5, 12, 20, 25, 27, 29}

In diseases of the esophagus, stomach, biliary tract, abdominal wall and genitourinary system, when there is full or partial resection, an interposition with an intestinal segment is performed definitively. In this procedure, disorders are frequent and when intense, can lead the patient into shock or even death.^{5, 7, 8, 9, 14, 16, 22, 26}

In interpositions with partial or total exclusion of the digestive track, segmental bypasses have shown changes in tissue and the pattern of mucus. The modification of the mucosa has been reported in disorders affecting the gastrointestinal tract. However, it is uncertain whether there is direct action of goblet cells or if mucus production is due to a chronic inflammation of the epithelium and whether changes occur in the villus and crypts.^{18, 19}

Simultaneous inflammatory condition of the stomach and intestinal mucosa induces gastrointestinal disorder which affects nutrition of the epithelial, causing damage such as mucosa ulceration, inflammatory infiltration and modification of the number of goblet cells in the affected segment.^{17, 23}

There are few studies on inflammation (neutrophil infiltration), the increased number of goblet cells, villus height and crypt depth in the jejunal or colon segment interposition during the long-term postoperative period.¹⁷ This study aims to evaluate the repercussions on interpositioned intestinal segments and thus corroborate to better define the use of this technique in several major operations, particularly in oncology.^{10, 18, 19, 30}

The objective of this research was to compare the interposition of a segment of jejunum with that of a colon in dogs, analyzing their clinical and surgical evolution and also the anatomopathological alterations of the interposed segments.

This project was approved by the Ethics Committee on Animal Experimentation (CETEA) UFMG, under protocol #144/2010. The research involved 40 mixed-breed male dogs, aged 36 to 72 months and weighing between 6 kg to 16 kg. The animals were immunized with the rabies vaccine and then dewormed. The dogs had continuous access to water, a balanced diet and were housed in individual cages with their respective records. The experiments were performed in the laboratories of the Veterinary School, UFMG

The research was comprised of two techniques for interposing segments of jejunum and transverse colon between the stomach and duodenum. The 40 dogs were numbered randomly and distributed into two groups of 20 animals. Even-numbered dogs formed group 1 (G1), chosen for gastrojejuno-duodenal interposition and odd numbered dogs formed group 2 (G2), chosen for gastrocoloduodenal interposition.

The study was developed in three phases: a) surgical technique; b) clinical observation of the animals in 16 intervals, from day 1 to day 120 (postoperative); c) reoperation, euthanasia and histology of the intestines at day 120 (post-euthanasia).

Pre-operative

The animals in groups G1 and G2 fasted for six hours before the operation and had no water for four hours. The dogs were pre-medicated with acepromazine 0.02% at a dose of 0.05 mg/kg body weight and Tramadol 50 mg/ml at a dose of 2 mg/kg body weight. Anesthesia was induced with propofol 1% at a dose of 5 mg/kg body weight, followed by tracheal intubation. Anesthesia was maintained on a partial rebreathing circuit with isoflurane gas and vaporization of a 1.5 minimum alveolar concentration, and maintained during surgery with spontaneous ventilation. Cephalothin antibiotic was used at a dose of 22 mg/kg body weight along with metronidazole (15 mg/kg) every 12 hours, started at induction of anesthesia and maintained 72 hours postoperatively. After the induction of anesthesia, the animals were immobilized and positioned in a supine position on a veterinary surgical table. Was performed extensive abdominal hair removal, disinfection with 80% alcohol and 2% povidone-iodine (PVPI), sterilizing the abdominal area. The animals were hydrated with 0.9% saline, 10 ml/kg/h during surgery.

Surgical technique used in G1

Each animal of both groups underwent a 15 cm laparotomy, an abdominal cavity examination, identification of the jejunum at the duodenojejunal angle and the transverse colon and study of the vascular arcades. After autonomization of an 8 cm jejunum segment, measured from the fixation point

at the duodenojejunal angle, with a maintained blood flow of the mesenteric vessels, was performed the transposition of the jejunum segment through an opening in the transverse mesocolon on the G1 animals. Isoperistaltic terminolateral anastomosis was done at the antrum and the second portion of the duodenum with 3.0 polydioxanone sutures. The opening of the mesocolon was sutured after review of the cavity, hemostasis and coagulation. Was performed the synthesis of the abdominal wall with separate sutures, using 2.0 nylon (Figure 1).

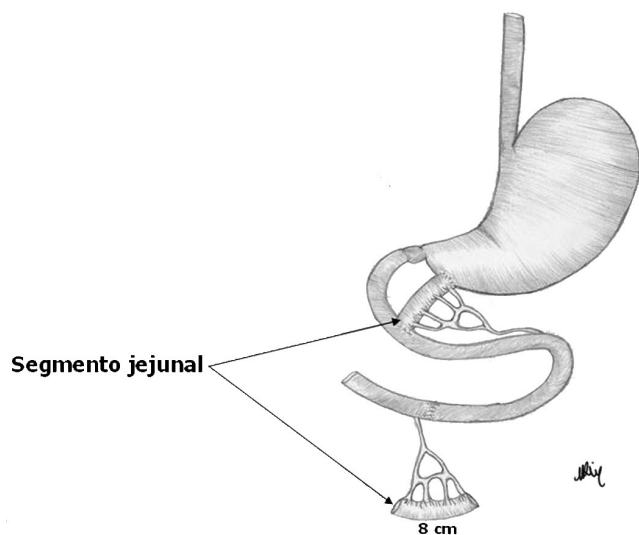


FIGURE 1 - Jejunum segment interposition

Surgical technique used in G2

This group followed the same technical procedure of intestinal interposition as G1; however, after laparotomy, was prepared a segment of transverse colon with an 8 cm extension irrigated by the middle colic artery (Figure 2).

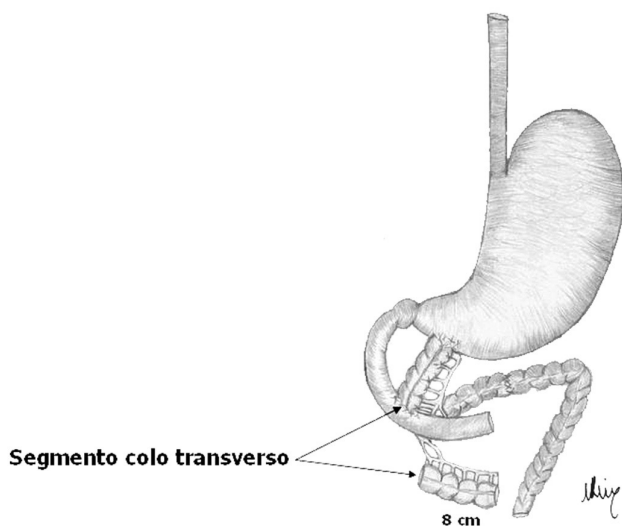


FIGURE 2 - Colon segment interposition

Postoperative

In the immediate postoperative period, G1 and G2 received water and an unrestricted diet. They were kept under observation and examined in 16 intervals from day 1 to day 120 after surgery. All data from each animal of both groups were entered in a spreadsheet to compare the two surgical techniques with emphasis on the following: weight (in kg) measured on the interval level, diarrhea, intestinal anastomotic fistulas, and complications of the surgical wound (infection, dehiscence, incisional hernia). The weight of the animals was measured in kilograms at prescribed intervals.

An anastomotic fistula was characterized by the elimination of gastrointestinal contents through the wound, without stratification or quantification.

Diarrhea was classified into five grades, according to the intensity and stool weight.

The infection, dehiscence and incisional hernia were evaluated on the ordinal level, ranging from grade 0 to grade 4 in order of increasing intensity, frequency and extent, being: grade 0, absent; grade 1, to 2.0 cm; grade 2, 2.1 to 4.0 cm; grade 3, 4.1 to 6.0 cm; grade 4, above 6.1 cm.

Reoperation, biopsies and euthanasia

On the 120th day after surgery, the animals of G1 and G2 were anesthetized and reoperated. Were evaluated the effects of the gastrojejunoduodenal and gastrocoloduodenal interposition. Initially, was macroscopically observed in situ the interposed segment as to the extension, vascularization, and general condition of the anastomosis and adhesions. Then was proceeded to remove the segments, including the entire anastomosis and small fragment of the gastric antrum and second portion of the duodenum. Was opened the segment along its entire length on the antimesenteric border and macroscopically evaluated the presence of mucus, mucosal integrity and consistency of the wall. Then, by raising the dose of anesthetic the animals were euthanized. Eight fragments were taken from across the intestinal wall, two on each anastomosis and four throughout the intestinal segment. These specimens were subjected to the action of Bouin's fixative and sent for anatomopathological examination.

Histology

The fragments of the G1 and G2 intestinal segments were fixed in a 10% formalin solution and kept for 30 minutes consecutively in baths of 70%, 80% and 90% absolute alcohol for dehydration. Then they were maintained in xylol for 30 minutes and lastly embedded in paraffin. Next, the fragments were sectioned at a 5m average thickness. Were prepared 320 slides, 160 from each group, staining the fragments with H&E. Were examined 320 slides and separated 120 from each group. Was randomly divided them into three groups of 40 samples for the study of the intensity of neutrophils, goblet cells, and the intestinal

villi and crypts. Were analyzed the 240 slides in 16 fields using Microsoft Office PowerPoint 2003. Was then extracted the arithmetic mean of the values obtained for comparison by analysis of variance using Fisher's exact test.

The intensity of neutrophil infiltration and goblet cells were determined on the ordinal level and divided into five grades (0-4), in order of increasing intensity and frequency, as described: grade 0, absent; grade 1, mild; grade 2, moderate; grade 3, severe; grade 4, uncountable.

Changes in intestinal villi and crypts were stratified into five grades (0-4) at the ordinal level, ranging in ascending order in intensity and frequency, as described: grade 0, no atrophy; grade 1, mild atrophy; grade 2, moderate atrophy; grade 3, severe atrophy; grade 4, fragmentation of villi and crypts.

Statistical Analysis

Was evaluated the condition of normality of variables with the Shapiro-Wilk test and considered values of $p < 0.05$ and $p < 0.001$ as statistically significant. The data were analyzed with the Statistical Package for Social Sciences-18 (SPSS). In the postoperative clinical evaluation, were used the Mann-Whitney and Fisher's exact tests for comparison of data obtained from G1 (gastrojejunoduodenal) and G2 (gastrocoloduodenal), when the data of the dependent variables were at the interval level. Was performed an analysis corresponding to the 16 intervals of the experiment for each variable studied.

RESULTS

Clinical evaluation

Clinical evaluation of the average initial postoperative weight of G1 and G2 showed no difference ($p = 0.866$). From the 16th period on, there was weight loss in both groups without significant differences between them, until the evaluation at 96 days. The 104th day to the 120th day after surgery, weight loss was more pronounced in G2, which had been submitted to the interposition of a colon segment ($p < 0.05$) (Table 1).

Diarrhea

All animals that underwent jejunal segment interposition had grade 2 and 3 diarrhea, while the ones submitted to colon segment interposition had grade 3 and 4 ($p < 0.001$) diarrhea (Fisher's exact test).

Fistula of the intestinal anastomosis

Fistulas, clinically controlled, occurred in 20% (four dogs) with jejunal interposition (G1) and 100% of those that underwent colon interposition (G2).

Complications of the surgical incision

Among the animals that underwent jejunal interposition, 16 dogs (80%) had no infection,

dehiscence, or incisional hernia and in four dogs (20%) the complications were grade 1. However, 16 dogs (80%) that underwent colon interposition had grade 2 complications and four (20%) had grade 4 complications (Table 2).

TABLE 1 - Dogs submitted to the gastrojejunoduodenal interposition (G1) and the gastrocoloduodenal interposition (G2): 16 intervals in 120 days postoperatively (n=40)

Period of assessment	Animal's weight		p - value
	G1	G2	
1 ^o day (kg)	9 (6-16)	9 (6-16)	0.866
8 ^o day (kg)	9 (6-16)	9 (6-16)	0.866
16 ^o day (kg)	8.9 (5.8-15.8)	8.75 (4.2-15.7)	0.222
24 ^o day (kg)	8.65 (5.4-15.5)	8.4 (4.1-15.5)	0.150
32 ^o day (kg)	8.45 (5.1-15.2)	8.05 (4-15.3)	0.285
40 ^o day (kg)	8.15 (5-15)	8.0 (4-15)	0.448
48 ^o day (kg)	7.95 (4.7-14.8)	7.8 (4-14,8)	0.393
56 ^o day (kg)	7.8 (4.5-14.6)	7.5 (4-14)	0.448
64 ^o day (kg)	7.7 (4.5-14.6)	7.4 (4-14)	0.393
72 ^o day (kg)	7.6 (4.5-14.6)	6.85 (4-13.7)	0.140
80 ^o day (kg)	7.6 (4.5-14.6)	6.8 (4-13.7)	0.098
88 ^o day (kg)	7.55 (4.5-14.6)	6.5 (4-13.6)	0.093
96 ^o day (kg)	7.5 (4.5-14.5)	6.2 (4-13.6)	0.090
104 ^o day (kg)	7.5 (4.5-14.5)	6.1 (4-13.5)	0.048*
112 ^o day (kg)	7.5 (4.5-14.5)	6 (4-13.4)	0.045*
120 ^o day (kg)	7.5 (4.5-14.5)	6 (4-13.3)	0.041*

* Significant differences ($p < 0.05$) Mann - Whitney

TABLE 2 - Comparison of the results of the clinical evaluation between G1 and G2, obtained postoperatively in 16 intervals from day 1 to day 120 (n=40)

Degree of variation	Complications in the surgical incision (infection, dehiscence, hernia)		p - value
	G1	G2	
0	16 (80%)	0	<0,001*
1	4 (20%)	0	
2	0	16 (80%)	
3	0	0	
4	0	4 (20%)	

* Significant differences ($p < 0.001$) Fisher's Exact Test

Macroscopic anatomopathological exam

Closed segment: under observation, the segment of jejunum had lengthened and the colon segment had shortened at an average of over 2 cm (jejunum) and 2 cm less for the colon. The diameters did not change. The movement of vessels involving the interposition, and bowel anastomoses was evident.

Open segment: large amounts of mucous fluid were found. The mucosa had slight homogeneous undulation and was flexible and soft to the touch. G1 had thick and abundant mucous and lumen firm to the touch. The G2 had slightly flexible pieces. The overall appearance of the mucous was normal and clear with a sharp luminal surface. The intensity was respectively 1 and 2 in 16 dogs and four dogs in G1. Furthermore, the intensity was respectively 3 and 4 in 14 dogs and six dogs in G2.

Optical microscopy

Were studied the alterations in the jejunal segment interposition (gastrojejunoduodenal) and in the colon segment interposition (gastrocoloduodenal) on day 120 under an optical microscope with the following results:

In the segment of jejunum

Grade 1 neutrophil infiltration was observed in 80% of the slides and grade 2 intensity in 20%; increased number of goblet cells in 80% of the slides at grade 1 intensity and 20% at grade 2; atrophy of the villi and crypts was observed in 80% of slides at grade 1 intensity and 20% at grade 2;

In the segment of the transverse colon

Neutrophil infiltration was observed in 70% of the slides at a grade 3 intensity with 30% at grade 4; 70% had goblet cells at grade 3 intensity and 30% were grade 4, the crypts of Lieberkühn had atrophy in 70% of the slides at grade 3 intensity and 30% were grade 4.

The comparison between the two groups showed that histological changes (neutrophil infiltration, increased numbers of goblet cells and atrophy of the villi and crypts) were more pronounced in the colon segment than in the jejunum segment. Significant differences ($p < 0.001$) Fisher's exact test.

DISCUSSION

Clinical evaluation

Many authors are unanimous in stating that developing a way to slow down gastrointestinal tract transit, through interposition, is of great importance for postoperative dogs with massive loss of intestine. In the animals whose technical procedure was not observed, the enteric content quickly reaches the large intestine, so the episodes of diarrhea are frequent and intense along with early body weight loss.^{4,5,7,8,9,13,14,15,16}

Weight loss was common in both groups during the experiment. In animals (G1) with gastrojejunoduodenal interposition, weight was more stable and began to vary at 24 days, with a tendency to stability in the final four intervals. The G1 animals did not show intolerance to the diet. In G2, with gastrocoloduodenal interposition, the majority of the group presented equilibrium from the 48th to 64th day. Then weight loss accelerated along with food intolerance and deterioration in general condition from the 80th day, with a tendency to equilibrate only in the last three postoperative intervals.

Intraoperatively were tested sutures of the anastomoses to minimize the possible space of continuity between them and the peritoneal cavity.

A punctuated fistula may trigger contamination, infection, sepsis and death. It is assumed that the occurrence of unnoticeable leakage of intestinal contents may have influenced the morbidity in the

groups. The preparation of the anastomosis in order to standardize it in each group with a jejunum or colon segment was not an easy mission. Therefore, the clinical significance, especially in colon segment interposition, was established by the intense alterations in G2 subjects.

Clinical evaluation between groups considered diarrhea, wound infection, fistula, dehiscence of the abdominal wall and incisional hernia (deterioration of general condition), occurrences arising from gastroduodenal interposition with jejunum and colon segments. All subjects were studied during the postoperative period of 120 days and comparisons were made between groups G1 and G2.

It can be observed that these manifestations added predisposing factors to the morbidity of the dogs.²²

The volume of postoperative intestinal excretion for 120 days was sometimes small in the beginning and increased later. It was found that, with the gastroduodenal interposition of jejunum and colon segments, diarrhea discharges affected the totality of dogs. In the group with jejunal segment interposition, diarrhea, although frequent, demonstrated a pasty content unchanged for long periods of time. There was less variation in G1. The development of diarrhea in animals with colon segment interposition was fluid diarrheal discharges, persistent and containing large amounts of mucous. There was greater variation in G2. The tendency to stabilize diarrheal episodes in the groups was in relation to weight loss, low intake of food and water, muscle atrophy and even ataxia. The possibility of adaptation of animals to the unfolding of a long postoperative course was quite remote. Dogs in G2 demonstrated faster intestinal transit, with no time for the completion of digestive processes.

Surgical complications

Wound infection coupled with events of gastrointestinal interposition with jejunum and colon segments was not rare during the experiment. At least four dogs with jejunal segment had wound infection, whereas the surgical incision in all animals with colon segment interposition was infected.

Interposition can trigger many complications, including depression in animals, a state that was prevalent and was not foreseen. It can also be made a correlation to the anastomosis in the pyloric antrum and the second portion of the duodenum, large dynamic sites with respect to gastric juice containing pepsin, rennin, lipase, hydrochloric acid and mucus; duodenal Brünner glands, bile and pancreatic juice; and factors such as hormones and adequate nutrition.^{4,5,7,8,17,21,26,27,28,29} The microbiota also interfered in both the gastrojejunoduodenal and gastrocoloduodenal interposition.²² The observation of the groups at the end of each weekly interval revealed different health status' among the 40 subjects. The determining

factor for the improvement of dogs was the jejunal interposition, which stabilized the losses before the end of the postoperative period. In the survey, the data highlighted the aspect of the differences when using jejunum and colon segments in the gastroduodenal interposition. It is also necessary to consider the skill of the surgeon and the operative technique for careful evaluation of the postoperative period. The animals in G1 had more balanced losses with jejunal segment interposition when compared to G2 with colon segment interposition.^{10,11}

Dehiscence of the abdominal wall in G1 and G2

After episodes of diarrhea and wound infection of the abdominal wall in the gastrointestinal interpositions of G1 and G2, it was only a matter of time, in the absence of some sutures, that the dehiscence was obvious along a greater or lesser extent of the suture. There were four dogs with dehiscence of the abdominal wall in G1 and in 20 dogs in G2, evidenced at some point during the course of the postoperative period. Was observed that animals with dehiscent areas in the abdomen contained skin with thick and fibrous tissue.

Fistula in intestinal anastomosis

In dogs submitted to the jejunal and colon segment interposition, the fistula was observed in animals by the intermittent moisture in the skin. This uncomfortable complication affected four G1 dogs and all G2 dogs. At certain intervals after surgery, G2 showed remission of most fistulas.

Incisional hernia

The hernia on the scar of the median wall of the abdomen of those submitted to the jejunum and colon segment interposition, was more a consequence of the opening of the peritoneal cavity associated with diarrhea. It erupted early, followed by wound infection, fistula, dehiscence and a worsening condition. The incisional hernia weaknesses in the wall of the abdomen struck four dogs in G1; protrusion with varying volumes (minor and major) affected all with colon segment interposition in G2. During anastomosis was found lengthening of the jejunum segment and contraction of the colon segment.^{8,24} However, the influence of the length and diameter of the contraction in bringing about weight loss and diarrhea was seen in the short segment and large diameter in G2 when compared to G1. The data correlated the diameter of the colon to weight loss, diarrhea being responsible for the weight loss that was prevalent in G2. Based on the mechanism of the anastomosis with jejunal and colon interposition, much has been done to avoid damaging effects^{1,2}. In the study, feeding behavior was closely related to body weight loss, evidenced by better weight balance in the group with jejunal segment interposition compared to the group with colon segment interposition. G1 did not manifest intolerance to diet or significant adverse

effects. G2, in its majority, showed intolerance to some form of diet and water.¹¹

Anatomopathological examination

In the post euthanasia period the data of the gastrojejunoduodenal and gastrocoloduodenal interpositions were recorded in a preliminary study regarding jejunum and colon segments as to: adhesions; vascularization, the state of anastomoses (in closed segments) and variations of mucus; sharpness of the intestinal lumen surface and appearance of the mucosal layer of the interpositioned segments (in open segments).

No data was found in medical literature for comparison with the values obtained postoperatively. Studies on post euthanasia anatomopathological alterations of the jejunum and colon of G1 and G2 are scarce.^{15,16,28}

In this study was found the ratio of the number of neutrophils, goblet cells, and levels of the villi and crypts in the segments of interposition. The localized neutrophil infiltration was evident on the lamina propria, along with the increased number of goblet cells lining the villi and crypts, the fibrous reaction associated with mononuclears as well as the atrophy of the villi and crypts and enlargement of the apical portion. This enlargement is due to the infiltration of blood vessels and the inflammatory reaction caused by the increased number of neutrophils (neutrophil infiltration), goblet cells, villous and crypt levels.

The mucous membrane is under the action of physiological and pathological trophic factors. The trophic factors that determine the physiological aspect of the intestinal mucous membrane are comprised by intraluminal, humoral and subsidiary elements.²³ Intraluminal factors absent in the defunctionalized segment induce mucosal hypoplasia.

The histological exam demonstrated that the jejunum and colon segments of the gastroduodenal interposition had decreased villus height and crypt depth and an increase in the proliferation of neutrophils and goblet cells. The mucosal humoral factors were not considered as relevant modifiers in the study of jejunum and colon segments.

Subsidiary trophic factors of great importance in the research were vascular since 2/3 to 3/4 of the intestinal wall vascularization is responsible for the mucosal blood flow, making it susceptible to ischemia. Was considered it responsible for the reduction of the mucous membrane in the colon segment in the form of chronic ischemia. It impacts both groups, but the trophic effect was most significant in animals with the colon segment, since acute ischemia is reversible while chronic ischemia is morbid. These possibilities regarding the influx of physiological trophic values need to be clarified through further study.^{9,11}

In G1 (with interposition gastrojejunoduodenal): neutrophil infiltration struck 20 dogs. Four of them were

at grade 2 intensity, that is, twice that occurred in the remaining dogs. Thus, were found different values of neutrophil activity in the inflammatory process in this segment in G1. The increase in goblet cells occurred in all subjects of the group. In four dogs the intensity was two times that of the other two dogs.

These values clearly suggest the existence of a mechanism for adjusting the goblet cells, thereby indicating that, similarly, other cells may be modified depending on the substance present.^{9,11} In relation to the villi and crypt levels in G1, four dogs were at grade 2 intensity, double the other dogs.

The finding of activity with different intensity in segments of jejunum can be explained by the presence of a microbial action with more or less virulence in G1.^{9,11}

The G2 (with gastrocoloduodenal interposition) demonstrated intense neutrophilic infiltration, mainly in the lamina propria. In the serosa, the reaction was associated with mononuclear cells, adhesions and fibrosis. In six dogs the occurrence was more intense and in the others, less intense. Was observed that the inflammatory process with neutrophil infiltration was distributed with different intensity; however, it was very high in G2.^{9,11} The increase in the number of goblet cells lining the crypts was higher in six dogs in G2, and lower in the other dogs. It's known that the microflora of the colon is different from that of the jejunum. This difference clearly confirms that the action of the mechanisms influenced the cellularity and adaptation of goblet cells more intensely or less intensely within G2.^{9,11} Was detected atrophy of the crypts and flattening of the apical portion. This flattening is due to dilation of the corium and the inflammatory infiltrate process. As to the level of the crypts in G2, hypotrophy was more intense in six dogs and in the other dogs, less intense. Evidence of activity with different effects on colon segments demonstrates virulent microbiota, but with higher intensity for some and less for the other dogs.^{6,11}

As to the structure of the mucosa biopsies of the jejunum compared with biopsies of the colon segment, there was a difference between the two procedures. Was found the aspect of villus height and crypt depth next to normal with gastrojejuno-duodenal interposition in G1. In G2, with gastrocoloduodenal interposition, there was decreased height and flattening of the Lieberkühn crypts with more intensity.^{5,9,11,18,20}

A simultaneous inflammatory condition of the mucosa of the stomach and intestines cause gastrointestinal distress that impact on nutrition, causing epithelial damage such as ulceration of the mucosa, inflammatory infiltration, modification in the synthesis and number of goblet cells and in mucous production.¹⁸ The increase in mucous production can coexist with increased number of goblet cells in the injured segment. However, excluded segments of the digestive tract have gradual atrophy of the mucous membrane, in particular of the villi and crypts. Even if

nutritional deficiency stimulates reduction of goblet cells, they can increase relative to the variety of existing cells in the mucous membrane. In this research, in the post-euthanasia period, was evaluated the increased number of neutrophils, goblet cells, and levels of the villus and crypts in jejunum and colon segments. However, was noted that, despite the brief existence of adverse conditions, goblet cells evidently persist in the production and secretion of mucous.^{6,9,12,18,19,30}

From the technical point of view the interposition of an intestinal segment for anastomosis between the stomach and the second portion of the duodenum is relatively easy. However, it can lead to changes that are to some extent, irreversible.^{5,8,14}

From this study, it can be considered that jejunal interposition is effective and less complicated than colon interposition.^{2,3,7,8}

Intestinal interpositions are relevant in several operations on the digestive tract. However, they are not exempt from immediate and long-term complications, and may cause death.

With this serious problem, the concern is to improve existing resources and create new possibilities.^{13, 16,25}

CONCLUSION

Jejunal segment interposition showed a better clinical outcome than the colon segment. The pathological changes of the jejunal segments were less pronounced than the changes of the colon.

REFERENCES

1. Abu Dayyeh BK, Lautz DB, Thompson CC. Gastrojejunal stoma diameter predicts weight regain after Roux - en-Y Gastric bypass. *Clin Gastroenterol Hepatol.* 2011; 9, (3): p. 228-33.
2. Aguilar-Nascimento J, Goeijzer J. Early feeding after intestinal anastomoses: risks or benefits? *Rev Med Bras.* 2002; 48: 348-52.
3. Altaf MA, Sood MR. The nervous system and gastrointestinal function. *Dev Disabil Rev.* 2008; 14: 87-95.
4. Altmann GG. Influence of bile and pancreatic, secretion, on the size of the intestinal villi in the rat. *Am J Anat.* 1971; 132: 167-77.
5. Altmann GG, Leblond CP. Factors influence villus size in the small intestine of adult rats, revealed by transpositions of intestinal segments *Am J Anat.* 1970; 127: 15-36.
6. Azuma Y, Shinohara M, Wang PL, Suese Y, Yasuda H, Ohura K. Comparison of inhibitory effects of local anesthetics on immune functions of neutrophils: *J Immunopharmacol.* 2000; 22: 789-96.
7. Barros PHF, Pereira FL, Gouvêia ES, Moricz A, Campos T, Szutan LA, David AL. Alongamento do intestino com tubo gástrico: estudo piloto em porcos. *Rev Col Bras Cir.* 2010; 37 (4): 284-87.
8. Bastos ES, Silva AC, Goffi FS, Lima GA. Alterações funcionais do intestino delgado nas ressecções intestinais. *Rev Hosp Clin Fac Med. Univ. São Paulo.* 1950; 5: 179-200.
9. Biondo-Simões MLP, Greca FH, Abicalaffe MD, Colnaghi MC, Mattos E Silva E, Yamasaki ES. Colite do cólon excluso: modelo experimental em ratos. *Acta Cir Bras.* 2000; 15 (supl: 3): 7-11.
10. Burns AJ, Roberts RR, Bornstein JC, Young HM. Development of the enteric nervous system and its role in intestinal motility during fetal and early postnatal stages. *Pediatr Surg.* 2009; 18: 196-205.
11. Buts JP, Morin CL, Ling V. Influence of dietary component on intestinal adaptation after small bowel resection in rats. *Clin Invest Med.* 1979; 2: 59-66.

12. Buttow NC, Santin M, Macedo LC, Teixeira CAN, Novakowski GS, Armelin TRB, Assmann K. Study of the myenteric and submucous plexuses after BAC treatment in the intestine of rats. *Biocell*. 2004; 28 (2): 135-42.
13. Diniz MT, Passos VM, Barreto SM, Linares DB, Almeida SR, Rocha AL. Different criteria for assessment of Roux - en - Y gastric bypass success: does only weight matter? *Obes Sur*. 2009 Oct; 19 (10): 1384-92.
14. Jensenius H. Results of experimental resections of the small intestine on dogs. Copenhagen. Arnold Busck 1945.
15. Kasai M, Shichisaburo A, Makino K. Reconstruction of the cervical esophagus with a pedicled jejuna graft. *Surg Gyn Obs*. 1965; 121: 102.
16. Lázaro da Silva A, Da Conceição SA, Silva MLA. Interposição de alça jejunal no tratamento cirúrgico megaesôfago chagásico. *Rev Ass Med Brasil*. 1987; 33: 94-98.
17. Lima TG, Magalhães MJ, Silva M, Azevedo NA. Histoquímica dos polissacarídeos nas glândulas caliciformes duodenais do *Equus caballus*. *Arq Cent Est Fac Odont*. 1974; 11: 77-84.
18. Martinez CAR. Avaliação do número de celular caliciformes nas criptas da mucosa colônica com e sem trânsito intestinal. *Rev Col Bras Cir*. 2012; 39 (2): 139-45.
19. Martinez CAR, Ribeiro ML, Gambero A, Miranda DD, Pereira JA, Nadal SR. The importance of oxigen free radicalis in the etiopathogenesis of diversion colitis in rat. *Acta Cir Bras*. 2010; 25 (5): 387-95.
20. Nonose R, Spadari AP, Máximo FR, Pereira JA, Martinez CAR. Tisse quantification of neutral and acid mucins in the mucosa of the colon with and without fecal stream in rats. *Acta Cir Bras*. 2009; 24 (4): 267-75.
21. Pascher A, Kohler S, Neuhaus P, Pratschke J. Present status and future perspectives of intestinal transplantation. *Transplant*. 2008; 21: 401-14.
22. Petroianu A, Carvalho E Carneiro BGM, Rodrigues FHOPC, Rocha RF. Avaliação da reinfeção peritoneal após peritonite fecal em ratos. *Rev Col Bras Cir*. 2004; 31 (2): 90-4.
23. Pravda J. Radical induction theory of ulcerative colitis. *World J Gastrointestinal*. 2005; 11 (16): 2371-84.
24. Rena CL, Lázaro DA Silva A, Barra AA, Furtado MCV, Rena RL. Alterações morfométricas da musculatura dos músculos longitudinal e circular de ratos submetidos à criação de piloros no intestino delgado. *Rev Col Bras Cir*. 2007; 34 (1): 41-7.
25. Savassi-Rocha PR, Gonçalves IPS, Oliveira LC, Bambirra EA, Salomé N. Histological and cytological aspects of neovaginas constructed with a pediculate colonic segment. *ABCD Arq Bras Cir Dig*. 2002; 15 (4): 153-5.
26. Schapiro M, Faria Netto AJ, Saad FA, Goldenberg S. Interposição de um segmento de colo distal entre cotos remanescentes de intestino delgado após ressecção de 90% do jejunoíleo. Estudo experimental no cão. *Rev Ass Med Brasil*. 1977; 23: 350-5.
27. Singleton JR, Redmond II, McMurray JE. Ileocecal resection and small bowel transit and absorption. *Ann Surg*. 1964; 159: 690-4.
28. Skinner MH, Merendino KA. Na experimental evaluation of na interposed jejunal segment between the esophagus and the stomach combined with upper gastrectomy in the prevention of the esophagitis and jejunitis. *Ann Surg*. 1954; 141: 201-7.
29. Swidsinski A, Ladhoff A, Pernyhaler A, Swidsinski S, Loening-Baucke V, Ortner M. Mucosal flora ia inflammatory bowel disease. *Gastroenterology*. 2002; 122 (1): 44-54.
30. Welters ID, Menzebach A, Langefeld TW, Menzebach A, Hempelmann G. Inibitory effects of S(-) and R-(p) bupivacaine on neutroffil function. *Acta Anesthesio Scand*. 2001; 45: 570-5.