

# SPOILED GRADIENT RECALLED ACQUISITION IN THE STEADY STATE FOR MAGNETIC RESONANCE IMAGING DIAGNOSIS OF CUSHING DISEASE

Carolina G.S. Leães, Júlia F.S. Pereira-Lima, Rene Lenhardt, Vera M.F. Silveira, Nelson P. Ferreira, Miriam C. Oliveira

Cushing disease (CD) is a rare and debilitating endocrinopathy caused by an adrenocorticotropin (ACTH)-secreting pituitary adenoma. The diagnosis of CD consists in signs, symptoms and laboratorial detection of endogenous hypercortisolism along with identification of the pituitary tumor<sup>1</sup>. Detection of ACTH-secreting pituitary adenomas by imaging techniques has always been a challenge. Gadolinium-enhanced magnetic resonance imaging (MRI) has diagnostic accuracy for CD ranging from 40 to 50%<sup>1,2</sup>, and new techniques, such as the spoiled gradient recalled acquisition in the steady state (SPGR) MRI have been developed to improve the rate of pituitary tumor detection<sup>3-5</sup>.

We report on a case in which SPGR MRI proved essential for achieving an accurate diagnosis of CD.

## CASE

A 48-year-old female presented with 12 months of weight gain, rounded and red face, hair loss, intense and activity-limiting fatigue, arthralgias, increase in blood pressure levels, and severe osteoporosis with schium fractures. She denied previous use of glucocorticoids or chronic diseases, headache or visual alteration. History of continued use of enalapril 20 mg qid, alendronate sodium 70 mg/week, calcium, 500 mg bid, vitamin D 200IU bid. On physical examination, she presented moon facies, facial plethora, blood pressure levels of 140/90 mmHg, buffalo hump, centripetal obesity, proximal upper and lower limb muscle weakness, and hair fragility. No violaceous striae, hirsutism or acne. Laboratory evaluation revealed basal cortisol levels at 8 h: 28.2 mg/dL; cortisol at 24 h: 26 mg/dL; 24-h cortisoluria: 303.4 (25–213.7 mg/24 h); basal ACTH: 58.6 (0–46 pg/mL); 0.5-mg dexamethasone suppression testing every 6 h for 8 doses: cortisol: 25.5 and 24-h cortisoluria: 740.0; 2-mg dexamethasone suppression testing every 6 h for 8 doses: cortisol: 20.1 and 24-h cortisoluria: 986.4.

Pituitary MRI showed normal pituitary gland (Fig 1) and com-

puted tomography (CT) scan of the chest and abdomen disclosed normal tomographic and morphological aspect of the adrenal glands, and a nodular image of 0.8 cm in the central region of the inferior lobe of the left lung, with density of soft parts, slightly wavy contour, and of uncertain evolutive nature and potential. Magnetic resonance images were reconstructed by means of three-dimensional SPGR, exhibiting a 0.4 × 0.3-cm posterolateral right-sided pituitary microadenoma; pituitary stalk with slightly asymmetric implantation corresponding to the anatomic variable (Fig 2). Inferior petrosal sinus sampling (IPSS) was performed after desmopressin stimulation (10 mg IV), which indicated ACTH hypersecretion from the right inferior petrosal sinus (Table). The patient underwent transsphenoidal surgery, with histological confirmation of the pituitary adenoma immunohistochemically positive for ACTH.

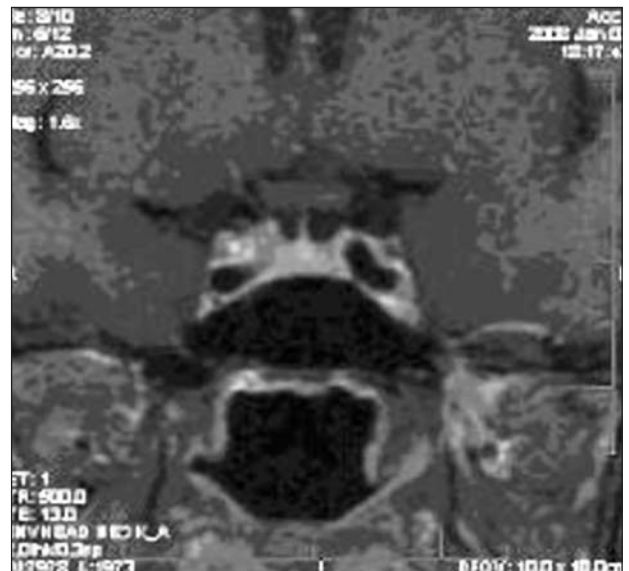

Fig 1. Conventional MRI Spin Echo demonstrating normal pituitary parenchyma

## RESSONÂNCIA MAGNÉTICA TRIDIMENSIONAL NO DIAGNÓSTICO DA DOENÇA DE CUSHING

Neuroendocrinology Center, Complexo Hospitalar Santa Casa, Universidade Federal de Ciências da Saúde de Porto Alegre (UFCSA), Porto Alegre RS, Brazil.

Received 7 July 2008, received in final form 30 September 2008. Accepted 10 November 2008.

Dra. Carolina Garcia Soares Leães – Rua Faria Santos 132 - 90670-150 Porto Alegre RS - Brasil. E-mail: dracarolina@cisa.med.br

Table. Results of inferior petrosal sinus sampling after desmopressin stimulation (10 mg IV) indicating ACTH hypersecretion from the right inferior petrosal sinus.

ACTH (0–46 pg/mL)	Time 0	Time 3 min after DDAVP	Time 5 min after DDAVP	Time 10 min after DDAVP
LIPS	58.0	37.4	29.9	138.0
RIPS	579.0	>1250.0	577.0	478.0
Peripheral	49.7	13.3	63.6	51.7

ACTH, adrenocorticotropin hormone; DDAVP, desmopressin; LIPS, left inferior petrosal sinus; RIPS, right inferior petrosal sinus.

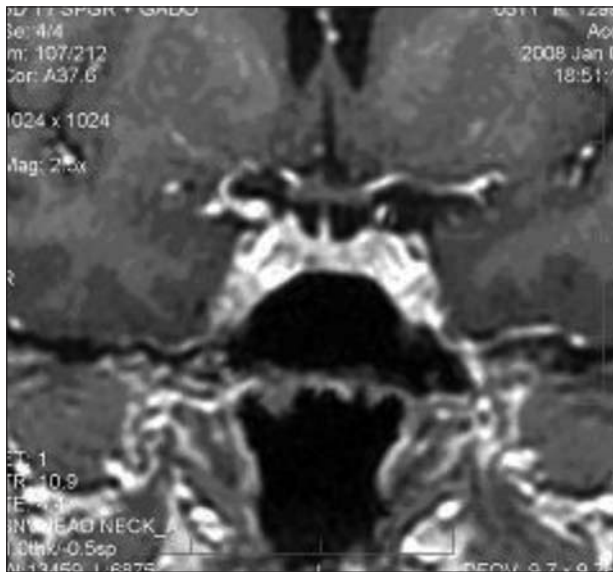


Fig 2. Three-dimensional SPGR MR image exhibiting a 0.4 × 0.3-cm posterolateral right-sided pituitary microadenoma (arrow). Pituitary stalk with slightly asymmetric implantation corresponding to the anatomic variable is observed.

## DISCUSSION

In the case presented here, the patient showed clinical features compatible with Cushing syndrome: centripetal obesity, buffalo hump, moon facies, facial plethora, proximal muscle weakness, muscular hypotrophy, hair fragility, hypertension, and osteoporosis<sup>1</sup>. Screening examinations were positive with increased 24-h cortisoluria and midnight cortisol. ACTH value >15 pg/mL suggested ACTH-dependent hypercortisolism. No suppression with high-dose dexamethasone associated with normal pituitary MRI and presence of small pulmonary nodule suggested an ectopic ACTH-secreting tumor. However, although the precise nature of the pulmonary nodule could not be confirmed, reconstruction MRI using the SPGR technique to identify right-sided pituitary microadenoma combined with the IPSS clearly positive result proved essential for achieving an accurate etiological diagnosis of CD. Classically, the diagnosis of CD is considered as an IPS/peripheral-ACTH ratio  $\geq 2.0$  in the basal state and  $\geq 3.0$  after stimulation. Moreover, a bilateral (left/right or right/left) IPS gradi-

ent  $\geq 1.4$  suggests lateralization of the lesion<sup>1</sup>. Although IPS catheterization has accuracy of only 57% for lateralization of the lesion due to asymmetries in venous drainage and tumor location close to the mean line, in the present case lateralization of the lesion could be clearly indicated (IPS gradient/peripheral-ACTH and baseline right/left=10.0 and=33.0 after stimulation).

However, some factors hinder the correct identification of the corticotropinomas, mainly their typically small size (90% of them are microadenomas)<sup>1,3</sup> and tendency to present signs and enhancement similar to those of the normal pituitary tissue<sup>3,4</sup>.

Recent studies have demonstrated that postgadolinium SPGR MRI doubled the detection rate of pituitary adenomas in adults<sup>3</sup> and children<sup>5</sup> when compared to conventional MRI with T1-weighted spin echo (SE) sequences. Patronas et al.<sup>3</sup> have demonstrated SPGR MRI sensitivity of 80% in the detection of corticotropinomas, superior to the 49% obtained by means of conventional MRI SE. Factors contributing to a better performance of SPGR MRI include superior soft tissue contrast and images obtained from thinner sections of 1 to 1.5 mm with consequently higher image resolution<sup>3,4</sup>. Furthermore, the SPGR method is characterized by faster acquisition of images, minimizing artifacts from motion and vascular pulsation<sup>3</sup>. Another recent application of this method is the intraoperative SPGR MRI as a surgical modality in transsphenoidal surgery, which allows a differentiation between normal pituitary tissue, residual tumor tissue, fibrosis, reactive inflammatory alterations, and hematoma formation, decreasing morbidity associated with the surgery and increasing overall success rate after surgery<sup>6</sup>.

It is important to recognize that in the case reported here, both studies were carried out simultaneously, discarding the possibility of different results between the techniques due to possible tumor growth.

The cure rate for CD patients with detected tumor is 80–90%, but drops to 50–70% when the lesion cannot be localized preoperatively<sup>7,8</sup>. Besides increasing the cure rate, the identification of the ACTH-secreting tumor decreases morbidity associated with CD in transsphenoidal

surgery, reducing the incidence of hypopituitarism and cerebrospinal fluid leak caused by multiple surgical pituitary exploration<sup>1,4</sup>. Thus, we highlight the importance of the development of techniques and use of associated high-accuracy imaging methods in these patients.

In conclusion, SPGR MRI proved superior to conventional MRI SE in the detection of pituitary tumors, especially of suspected corticotropinomas. For this reason, the authors suggest the inclusion of this method in the evaluation protocol for these lesions.

#### REFERENCES

1. Saad MJA, Maciel RMB, Mendonça BB. *Endocrinologia*. São Paulo: Atheneu, 2007:81-96.
2. Davis WL, Lee JN, King BD, Harnsberger HR. Dynamic contrast-enhanced MR imaging of the pituitary gland with fast spin-echo technique. *J Magn Reson Imaging* 1994;4:509-511.
3. Patronas N, Bulakbasi N, Stratakis CA, et al. Spoiled gradient recalled acquisition in the steady state technique is superior to conventional postcontrast spin echo technique for magnetic resonance imaging detection of adrenocorticotropin-secreting pituitary tumors. *J Clin Endocrinol Metab* 2003;88:1565-1569.
4. Batista D, Courkoutsakis NA, Oldfield EH, et al. Detection of adrenocorticotropin-secreting pituitary adenomas by magnetic resonance imaging in children and adolescents with Cushing disease. *J Clin Endocrinol Metab* 2005;90:5134-5140.
5. Lafferty AR, Patronas NJ, Goldberg P, Oldfield EH, Stratakis CA. The diagnostic accuracy of pituitary magnetic resonance imaging is enhanced by the use of fast spoiled grass. *Pediatr Res* 1999;45:92.
6. Pergolizzi RS Jr, Navabi A, Schwartz RB, et al. Intra-operative MR guidance during trans-sphenoidal pituitary resection: preliminary results. *J Magn Reson Imaging* 2001;13:136-141.
7. Moshang T Jr. Cushing's disease, 70 years later: and the beat goes on. *J Clin Endocrinol Metab* 2003;88:31-33.
8. Barrou Z, Abecassis JP, Guillaume B, et al. Magnetic resonance imaging in Cushing disease: prediction of surgical results. *Presse Med* 1997;26:7-11.