

Editorial

# Neuromyelitis optica spectrum disorders and beyond: telling a story one hundred years later

## *Distúrbios do espectro da neuromielite óptica e além: contando uma história cem anos depois*

Denis Bernardi Bichuetti<sup>1</sup> <sup>1</sup> Universidade Federal de São Paulo, Escola Paulista de Medicina, São Paulo SP, Brazil

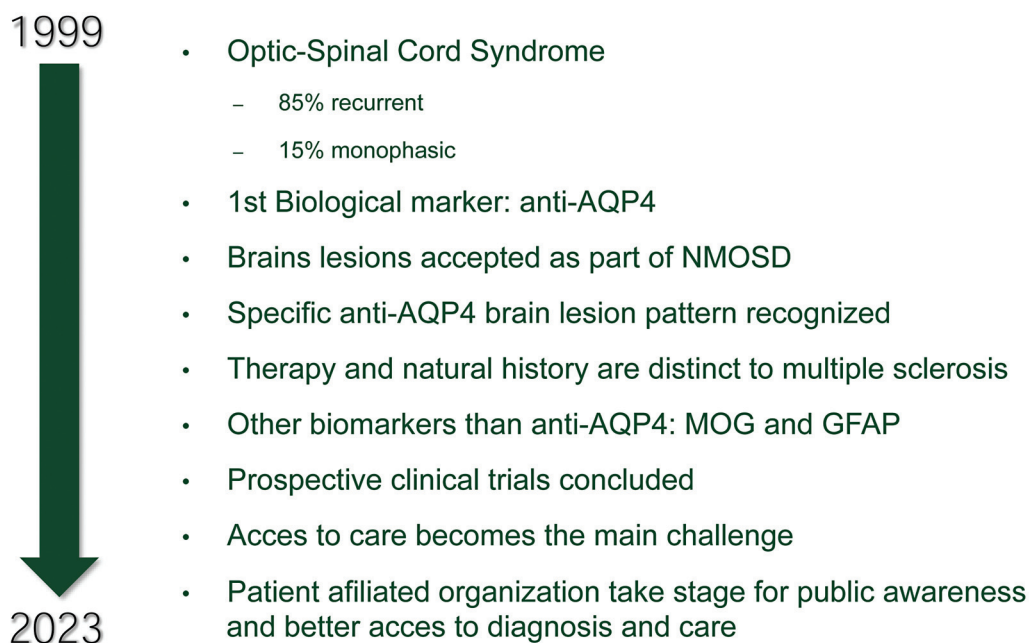
Arq. Neuropsiquiatr. 2023;81:513–514.

To write about neuromyelitis optica spectrum disorders (NMOSD) is to tell a story. A story that starts in the late 19th century with the first case series assembled by Eugene Devic and his student, Fernand Gault<sup>1</sup> and fasts forwards one hundred years to 1999, with the establishment of the first set of diagnostic criteria, which detached NMO from a

multiple sclerosis variant to set its own clinical grounds (► **Figure 1**).

From that moment on, within ten years of research, it has been discovered and explained more about NMOSD pathophysiology and central nervous system (CNS) autoimmunity than in all years of demyelinating disease research so far. The

### NMOSD: THE EVOLUTION OF A CONCEPT

**Figure 1**

Address for correspondence  
Denis Bernardi Bichuetti,  
(email: bichuetti@unifesp.br).

DOI <https://doi.org/10.1055/s-0043-1770932>.  
ISSN 0004-282X.

© 2023. The Author(s).

This is an open access article published by Thieme under the terms of the Creative Commons Attribution 4.0 International License, permitting copying and reproduction so long as the original work is given appropriate credit (<https://creativecommons.org/licenses/by/4.0/>).

Thieme Revinter Publicações Ltda., Rua do Matoso 170, Rio de Janeiro, RJ, CEP 20270-135, Brazil

received  
June 6, 2023  
accepted  
June 7, 2023

narrative encompasses three sets of diagnostic criteria (1999, 2006, and 2015), at least two autoantibodies (anti-AQP4 and anti-MOG), four-phase three randomized controlled trials (eculizumab, inebilizumab, satralizumab and ravalizumab), an international collaborative foundation (<https://guthy-jacksonfoundation.org>), national initiatives that joined patients and clinicians (<https://cdd.org.br> and <https://www.nmobrasil.com.br>, to cite the larger two), and lots (really a lot) of observational, retrospective, and prospective data (countless references).

All along this story there are many Brazilian researchers, some that joined efforts in gathering observational clinical, epidemiological, and treatment analysis data,<sup>2-8</sup> taking active part in consensus diagnosis criteria<sup>9</sup> and even antibody discovery.<sup>10</sup> Not to emphasize (even more) our importance in this tale, there are many more physicians and researchers that contributes to this puzzle with increasing basic and clinical science research, and even more everyday caring for patients with NMOSD and Myelin oligodendrocyte glycoprotein antibody-associated disease (MOGAD) in the under resourced Brazilian Unified Health System (*Sistema Único de Saúde* [SUS]) (impossible to cite all).

In the early ages of NMOSD, it was recognized only as an optico-spinal disease, but further along these years, the combined efforts of many disclosed that numerous patients suffer not only from brainstem syndromes, but diencephalic and encephalic inflammatory syndromes in distinct presentations. But... as things get more complex and we all get to know more about the pathophysiology of NMOSD, we are now aware that under this clinical umbrella there might actually be very distinct diseases, with different immunological mechanisms of central nervous system injury. At the moment, as I write this editorial, we are sentient of anti-AQP4 with its major complement and IL6 driven process, anti-MOG as an oligodendrocyte targeted inflammatory disease and anti-GFAP, thought with a very distinct clinical phenotype. Maybe in the future even more branches are added to this road.

In this issue of *Arquivos de Neuro-Psiquiatria*, Dr. Fragozo and colleagues<sup>11</sup> from Universidade de São Paulo and Pontifícia Universidade Católica do Rio Grande do Sul add some pages to this book by analyzing and categorizing imaging data from three sets of patients under this umbrella: those positive for anti-AQP4, positive for anti-MOG and double negative NMOSD.

Helping clinicians and patients that do not have access to antibody testing and relay only in clinical and imaging information to establish which syndrome is in front of them is of uttermost importance, especially for those practicing in underdeveloped or restricted resource settings, and for this reason we welcome the article from Dr. Fragozo and colleagues for establishing their differences and categorizing magnetic resonance imaging (MRI) data.

Still, it is worth emphasizing, as I recently heard in an international meeting, that “you do not have the final diagnosis until you earn it, and you earn it with the antibody”, especially when we are conscious that, based on the above-mentioned randomized controlled trials, some drugs might

not work so well for anti-AQP4 negative subjects. So, having clinical and MRI helping us to establish which syndrome is in front us does not excuse us as physicians and medical society that we need to stress for universal access to antibody testing and better academic funding for immunological research that guide us on improved caring for all these patients. That shall be the next page to this story, *em alguns momentos escrita em português do Brasil!*

P.S.: I would like to extend apologies and acknowledge that I was not able to cite all Brazilian authors, physicians and organizations involved in research and care for patients with NMOSD. Everyone and every action counts.

#### Conflict of Interest

As of June 2023, Denis Bichuetti has received speaking/consulting honoraria and/or travel expenses to scientific meetings sponsored by Merck Serono, TEVA Pharmaceuticals, Biogen Idec, Bayer Health Care Pharma, Genzyme Sanofi Aventis, Novartis, Roche, Astra Zeneca, Pfizer, Horizon and Alexion.

#### References

- Gault F De la Neuromyéélite Optique Aigue Paris 1894 [Cópia digital da tese de Fernad Gault]. Available from: <http://web2.bium.univ-paris5.fr/livanc/?cote=epo1112&do=pages>
- Papais-Alvarenga RM, Miranda-Santos CM, Puccioni-Sohler M, et al. Optic neuromyelitis syndrome in Brazilian patients. *J Neurol Neurosurg Psychiatry* 2002;73(04):429-435
- Bichuetti DB, Oliveira EM, Souza NA, Rivero RL, Gabbai AA. Neuromyelitis optica in Brazil: a study on clinical and prognostic factors. *Mult Scler* 2009;15(05):613-619
- Adoni T, Lino AM, da Gama PD, et al. Recurrent neuromyelitis optica in Brazilian patients: clinical, immunological, and neuroimaging characteristics. *Mult Scler* 2010;16(01):81-86
- Alves-Leon SV, Pimentel ML, Sant'Anna G, Malfetano FR, Estrada CD, Quirico-Santos T. Immune system markers of neuroinflammation in patients with clinical diagnose of neuromyelitis optica. *Arq Neuropsiquiatr* 2008;66(3B):678-684
- Brum DG, Barreira AA, dos Santos AC, et al. HLA-DRB association in neuromyelitis optica is different from that observed in multiple sclerosis. *Mult Scler* 2010;16(01):21-29
- Fukuda TG, Silva ITF, Dos Santos TSS, Filho MBP, de Abreu FF, Oliveira-Filho J. Clinical and prognostic aspects of patients with the Neuromyelitis Optica Spectrum Disorder (NMOSD) from a cohort in Northeast Brazil. *BMC Neurol* 2022;22(01):95
- Lana-Peixoto MA, Talim NC, Pedrosa D, Macedo JM, Santiago-Amaral J. Prevalence of neuromyelitis optica spectrum disorder in Belo Horizonte, Southeast Brazil. *Mult Scler Relat Disord* 2021; 50:102807
- Wingerchuk DM, Banwell B, Bennett JL, et al; International Panel for NMO Diagnosis. International consensus diagnostic criteria for neuromyelitis optica spectrum disorders. *Neurology* 2015;85(02):177-189
- Sato DK, Callegaro D, Lana-Peixoto MA, et al. Distinction between MOG antibody-positive and AQP4 antibody-positive NMO spectrum disorders. *Neurology* 2014;82(06):474-481
- Fragoso DC, Salles LMOP, Pereira SLA, Callegaro D, Kazutoshi D, Rimkus CM. AQP4-IgG NMOSD, MOGAD, and double-seronegative NMOSD: is it possible to depict the antibody subtype using magnetic resonance imaging? *Arq Neuropsiquiatr* 2023;81(05): 533-543