

SYMPTOMATIC THORACIC SPINAL CORD COMPRESSION CAUSED BY POSTSURGICAL PSEUDOMENINGOCELE

Arthur de Azambuja Pereira Filho¹, Gustavo de David²,
Gustavo de Azambuja Pereira Filho³, Albert Vincent Berthier Brasil⁴

ABSTRACT - We report the first case of symptomatic thoracic spinal cord compression caused by postsurgical pseudomeningocele. A 49-year-old man sought treatment for progressive loss of strength in the lower extremities ten months after full neurological recovery for a thoracic (T11) intradural-extramedullary schwannoma. Magnetic resonance imaging revealed a postsurgical thoracic (T11-T12) pseudomeningocele. The surgical approach showed an inadequate dural closure with spontaneous cerebrospinal fluid fistula. The defect was sealed with suture, muscle and biological glue covering. The patient had a good recovery. Pseudomeningocele must take part of the differential diagnosis of myelopathy after thoracic spine surgery.

KEY WORDS: pseudomeningocele, spinal cord compression, myelopathy.

Compressão medular torácica sintomática causada por pseudomeningocele pós-operatória

RESUMO - Relatamos o primeiro caso de compressão medular torácica sintomática causada por pseudomeningocele pós-operatória. Paciente masculino, 49 anos, apresentou perda progressiva de força nas extremidades inferiores dez meses após recuperação neurológica completa de cirurgia para remoção de schwannoma intradural-extramedular torácico. A ressonância magnética dorsal revelou pseudomeningocele (T11-T12). A abordagem cirúrgica mostrou fechamento dural inadequado com fistula líquórica espontânea. O defeito foi corrigido com sutura, músculo e cola biológica. O paciente teve boa evolução pós-operatória. Pseudomeningocele deve fazer parte do diagnóstico diferencial de mielopatia surgida após cirurgia na coluna dorsal.

PALAVRAS-CHAVE: pseudomeningocele, compressão medular, mielopatia.

Pseudomeningoceles are defined as extradural collections of cerebrospinal fluid (CSF) with no dural covering, which usually result from an inadvertent meningeal tear or inadequate closure during spinal surgery¹⁻⁴. Most pseudomeningoceles remain embedded in the paraspinal soft tissue and cause no symptoms⁵. Pseudomeningocele is an extremely rare cause of spinal cord compression. Few cases have been reported in the literature and in all of them the spinal cord compression was located in the cervical region⁶⁻⁹.

We describe a case of symptomatic thoracic spinal cord compression caused by postsurgical pseudomeningocele. To our knowledge, this is the first reported case of a thoracic postsurgical pseudomeningocele causing symptomatic spinal cord compression.

CASE

History and examination – A 49-year-old Caucasian man sought treatment after experiencing the development of progressive motor loss in the lower extremities for the last three months. The patient had undertaken a previous neurosurgical approach for a thoracic schwannoma ten months earlier, with a history of full neurological recovering after the surgery.

The patient's neurological examination showed decreased strength in both the lower limbs (he could walk with aid), with bilateral Babinsky sign, without sensory, bowel or bladder findings. All other aspects of neurological examination were intact.

The palpation of the operative wound showed no abnormality.

Neuroimaging investigation – Magnetic resonance imag-

Hospital São José / Complexo Hospitalar Santa Casa de Porto Alegre RS, Brazil: ¹Medical, Resident in Neurosurgery at Hospital São José - Complexo Hospitalar Santa Casa (HSJ/CHSC). ²Neurosurgeon at Hospital Tacchini - Bento Gonçalves, RS. ³Medical Student, Complexo Hospitalar Santa Casa / Fundação Faculdade Federal de Ciências Médicas de Porto Alegre (FFFCMPA). ⁴Neurosurgeon at HSJ-CHSC.

Received 2 August 2006, received in final form 27 October 2006. Accepted 18 December 2006.

Dr. Arthur de Azambuja Pereira Filho - Avenida Oscar Pereira 3008 - 91710-000 Porto Alegre RS - Brasil. E-mail: arthurpereirafilho@gmail.com

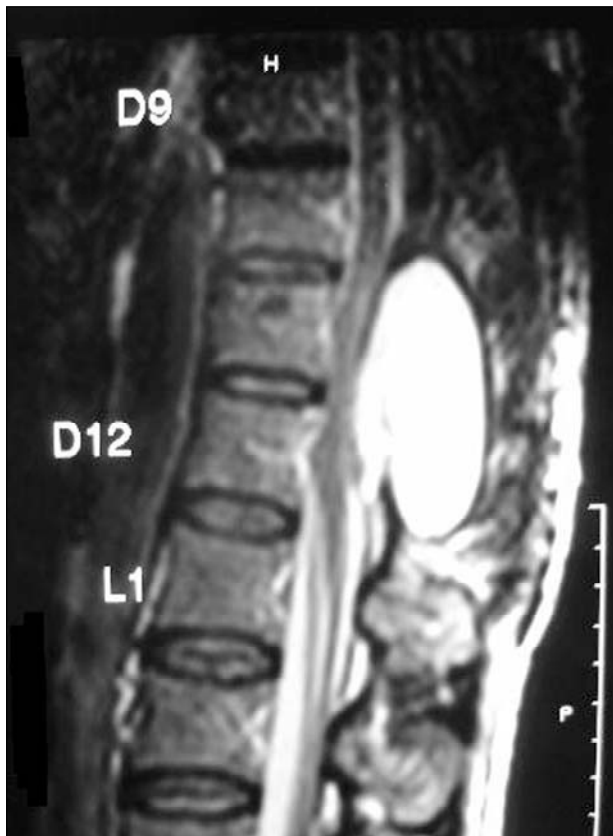


Fig 1. T2-weighted sagittal spinal MRI demonstrates large CSF collection at T11-T12 levels.

ing (MRI) revealed a postsurgical thoracic pseudomeningocele extending from T11 to T12 (Fig 1).

Surgical treatment – An external cerebrospinal fluid lumbar drain was placed preoperatively and kept closed during all the surgical procedure. The previous wound was reopened and a high tension encapsulated cerebrospinal fluid collection was identified. The pseudomeningocele was incised and the defect in the dural closure was seen with the aid of a *Valsalva* maneuver (Fig 2). The defect was sealed with suture and muscle with biological glue covering. Continuous CSF drainage was performed for five days.

Postoperative course – The patient had a good postoperative recovery. The lower limbs' strength had a mild improvement immediately. The patient was discharged 4 days after the surgery.

At a 6-months review, the patient's neurological examination was normal and the postoperative MRI showed resolution of the pseudomeningocele (Fig 3).

The patient agreed with the publication of his case.

DISCUSSION

The most common causes of spinal cord compression are: trauma, neoplasia, degenerative disease, epidural or subdural spinal hematoma, inflammatory disease and infection¹⁰⁻¹⁷. Postoperative pseudomeningocele is an extremely rare cause of spinal cord

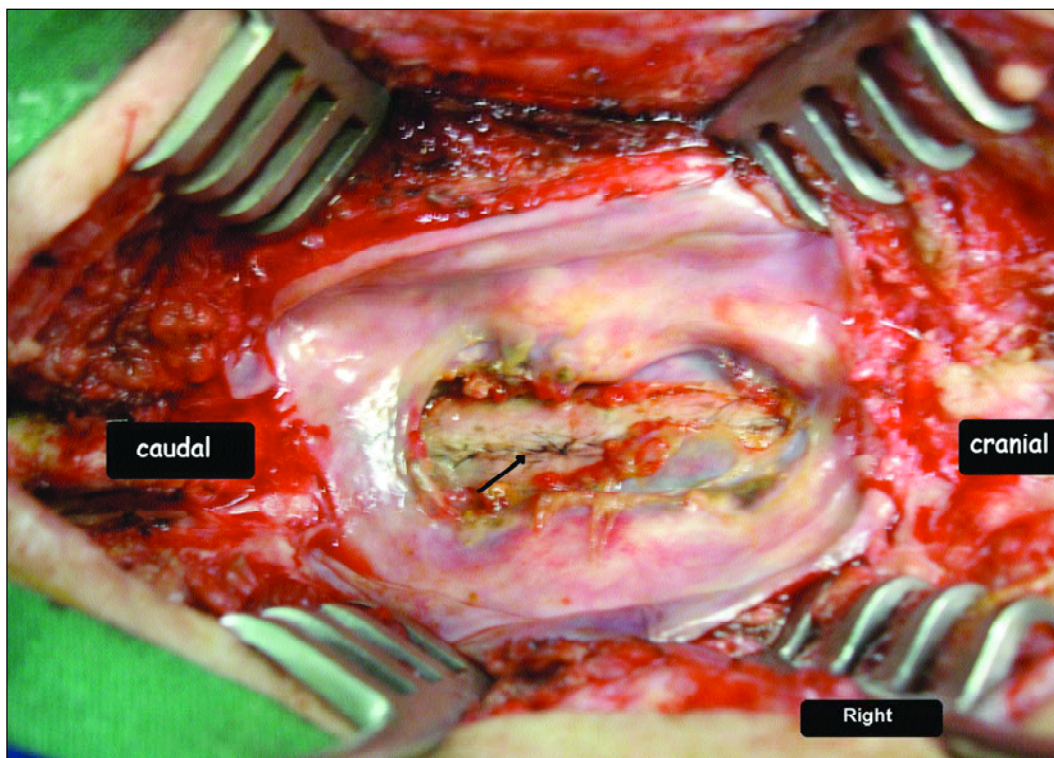


Fig 2. Transoperative photography demonstrates the pseudomeningocele's cavity and the defect in the dural closure (arrow).

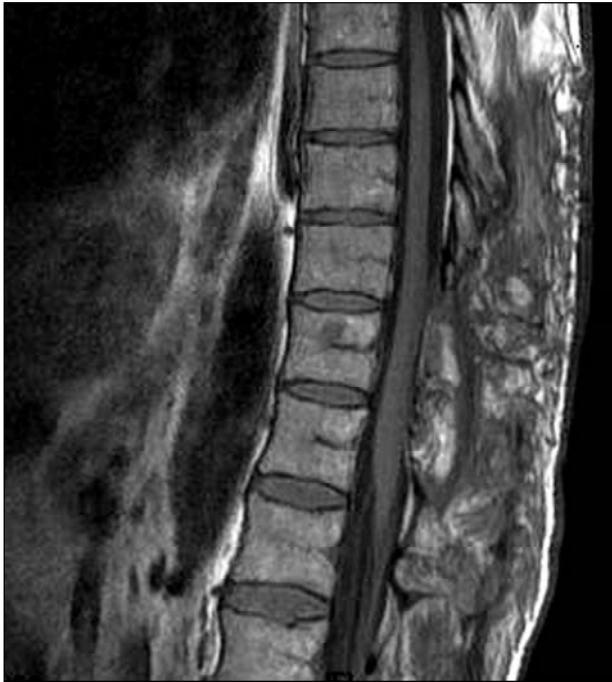

Fig 3. Postoperative T1-weighted sagittal spinal MRI shows the resolution of the pseudomeningocele.

compression⁶⁻⁹. A postlaminectomy pseudomeningocele was reported first in 1946 by Hyndman and Gerber in a review of extradural cysts¹⁸. In 1947, Swanson and Fincher¹⁹ reported the first three cases of pseudomeningocele after a lumbar discectomy. Winkler and Powers²⁰ reported two additional cases of pseudomeningocele after a lumbar discectomy and treated both patients with an excision of the meningocele and spinal fusion. Myelopathy due to pseudomeningocele was only reported four times, but in all cases the spinal cord compression was located in the cervical region⁶⁻⁹.

The incidence of a postsurgical pseudomeningocele is unknown as many cases probably are asymptomatic²¹. Swanson and Fincher¹⁹ reported a 0.068% incidence of pseudomeningoceles in 1700 exploratory laminectomies. Teplick et al.² noted that 2% of 400 laminectomy patients who underwent postoperative CT scanning had a pseudomeningocele.

The term pseudomeningocele reflects the absence of a true meningeal layer lining the cyst wall²¹. The formation of a pseudomeningocele begins with a tear in the dura that is closed incompletely or goes unnoticed at the time of a laminectomy. If the arachnoid remains intact, there may be herniation of the arachnoid through the dural opening resulting in an arachnoid-lined cyst^{2,20,22,23}. More commonly, the dura and arachnoid are lacerated, and the CSF pours into

the paraspinal soft tissue. The CSF may be absorbed initially, but the CSF collection eventually becomes encapsulated by fibrous tissue^{1,2,24,25}.

The optimal selection of diagnostic imaging techniques is debated in the literature. CT scanning has been considered in the diagnosis of postoperative pseudomeningocele. Identification of the neck of the pseudomeningocele is improved with the intrathecal administration of water-soluble contrast^{2,26,27}. Although myelography demonstrates the pseudomeningocele, the communication between the meningocele sac and the thecal sac usually is not well visualized. The use of MRI in the evaluation of postoperative pseudomeningoceles has been reported since 1988^{27,28}. MRI studies can provide excellent definition of the meningocele and its communication with the dural sac. It is considered the *gold-standard* method in diagnosing postoperative pseudomeningoceles²⁸. Digital subtraction myelography is also reported in the literature with good results²⁹.

Pseudomeningoceles can be either symptomatic or not. According to Lee et al.²¹, it may be difficult to determine the real source of symptoms in patients with a history of local surgery and radiological evidence of a pseudomeningocele. Tension of the cyst against the spinal cord or the nerve roots, entrapment of nerve roots into the dural defect, or periradicular fibrosis can be responsible for the patient's complaints^{21,26}.

The treatment of a postoperative pseudomeningocele is somewhat controversial. Asymptomatic pseudomeningoceles may be left untreated; however, it may be difficult to confirm that the pseudomeningocele is truly asymptomatic. The definitive treatment of a symptomatic postoperative pseudomeningocele is surgical and requires adequate exposure in order to localize the dural defect²⁶. The dura should be closed primarily, if at all possible. Fibrin glue along the suture line may be helpful^{1,26}. The removal of the entire pseudomeningocele sac is unnecessary according to the literature²⁶. Some authors refer other options for the treatment of pseudomeningoceles, such as peritoneal shunt³⁰ and mechanical compression³¹, but we consider these techniques as alternative treatments and our preference is almost always for the aggressive surgical repair.

Lumbar spinal fluid drainage is a common procedure to reduce the risks of CSF fistula after various transdural neurosurgical procedures³². Although it is an effective procedure, some serious complications may ensue. Common adverse events observed with

lumbar spinal fluid drainage are infections, pneumocephalus, hematoma, and CSF overdrainage³². In the present case, we decided to maintain the lumbar drainage for five days, and no complication occurred. No evidence of treatment failure was observed six months after the procedure.

In conclusion, pseudomeningocele must take part of the differential diagnosis of progressive myelopathy after thoracic spine surgery. Surgical treatment of this entity seems to be effective.

REFERENCES

- Barron JT. Lumbar pseudomeningocele. *Orthopedics* 1990;113:608-610.
- Teplick JG, Peyster RG, Teplick SK, et al. CT identification of postlaminectomy pseudomeningocele. *AJNR* 1983;4:179-182.
- D'Andrea F, Maiuri F, Corriero G, et al. Postoperative lumbar arachnoidal diverticula. *Surg Neurol* 1985;23:287-290.
- Kim YW, Unger JD, Grinsell PJ. Postoperative pseudodiverticular (spurious meningoceles) of the cervical subarachnoid space. *Acta Radiol Diagn* 1974;15:16-20.
- Paolini S, Ciappetta P, Piattella MC. Intraspinous postlaminectomy pseudomeningocele. *Eur Spine J* 2003;12:325-327.
- Hosono N, Yonenobu K, Ono K. Postoperative cervical pseudomeningocele with herniation of the spinal cord. *Spine* 1995;20:2147-2150.
- Hanakita J, Kinuta Y, Suzuki T. Spinal cord compression due to postoperative cervical pseudomeningocele. *Neurosurgery* 1985;17:317-319.
- Helle TL, Conley FK. Postoperative cervical pseudomeningocele as a cause of delayed myelopathy. *Neurosurgery* 1981;9:314-316.
- Burres KP, Conley FK. Progressive neurological dysfunction secondary to postoperative cervical pseudomeningocele in a C-4 quadriplegic: case report. *J Neurosurg* 1978;48:289-291.
- Held JL, Peahota A. Nursing care of the patient with spinal cord compression. *Oncol Nursing Forum* 1993;20:1507-1516.
- Bucholtz JD. Metastatic epidural spinal cord compression. *Sem Oncol Nursing* 1999;15:150-159.
- Quinn JA, DeAngelis LM. Neurological emergencies in the cancer patient. *Sem Oncol* 2000;27:311-321.
- Bucholtz JD. Central nervous system metastases. *Sem Oncol Nursing* 1999;14:61-72.
- Abraham J. Management of pain and spinal cord compression in patients with advanced cancer. *Ann Intern Med* 1999;131:37-46.
- Gleave JRW, MacFarlane R. Cauda equina syndrome: what is the relationship between timing of surgery and outcome? *Br J Neurosurg* 2002;16:325-328.
- Healey J H, Brown H K. Complications of bone metastases. *Cancer* 2000;88:2940-2951.
- Markman N. Early recognition of spinal cord compression in cancer patients. *Cleve Clin Med J* 1999;66:629-631.
- Hyndman OR, Gerber WF. Spinal extradural cysts, congenital and acquired: report of cases. *J Neurosurg* 1946;3:474-486.
- Swanson HS, Fincher EF. Extradural arachnoidal cysts of traumatic origin. *J Neurosurg* 1947;4:530-538.
- Winckler H, Powers JA. Meningocele following hemilaminectomy. *N C Med J* 1950;11:292-294.
- Lee KS, Hardy IM. Postlaminectomy lumbar pseudomeningocele: report of four cases. *Neurosurgery* 1992;30:111-114.
- Rinaldi I, Hodges TO. Iatrogenic lumbar meningocele: report of three cases. *J Neurol Neurosurg Psychiatry* 1970;33:484-492.
- Rinaldi I, Peach WF. Postoperative lumbar meningocele: report of two cases. *J Neurosurg* 1969;30:504-507.
- Miller PR, Elder FW. Meningeal pseudocysts (meningocele spurius) following laminectomy. Report of ten cases. *J Bone Joint Surg* 1968;50:268-276.
- Pagni CA, Cassinari V, Bernasconi V. Meningocele spurius following hemilaminectomy in a case of lumbar discal hernia. *J Neurosurg* 1961;18:709-710.
- Hadani M, Findler G, Knoler N, et al. Entrapped lumbar nerve root in pseudomeningocele after laminectomy: report of three cases. *Neurosurgery* 1986;19:405-407.
- Schumacher H-W, Wassman H, Podlinski C. Pseudomeningocele of the lumbar spine. *Surg Neurol* 1988;29:77-78.
- Murayama S, Numaguchi Y, Whitecloud TS, et al. Magnetic resonance imaging of postsurgical pseudomeningocele. *Comput Med Imaging Graph* 1989;13:335-339.
- Phillips CD, Kaptain GJ, Razack N. Depiction of a postoperative pseudomeningocele with Digital Subtraction Myelography. *Am J Neuroradiol* 2002;23:337-338.
- Andrew SA, Sidhu KS. Cervical-peritoneal shunt placement for postoperative cervical pseudomeningocele. *J Spinal Disord Tech* 2005;18:290-292.
- Leis AA, Leis JM, Leis JR. Pseudomeningoceles: a role for mechanical compression in the treatment of dural tears. *Neurology* 2001;56:1116-1117.
- Bloch J, Regli L. Brain stem and cerebellar dysfunction after lumbar spinal fluid drainage: case report. *J Neurol Neurosurg Psychiatry* 2003;74:992-994.