

SUBCLINICAL RHYTHMIC ELECTROGRAPHIC DISCHARGE IN ADULTS

AN ATYPICAL EVOLUTION

DÉLRIO F. SILVA*, EDMAR ZANOTELI**, MÁRCIA MARQUES LIMA***, RENATO ANGHINAH***, JOSÉ GERALDO C. LIMA****

SUMMARY - The subclinical rhythmic electrographic discharge in adults (SREDA) has been rarely reported. We describe the case of a 71 year-old man with transient ischemic attack, whose EEG showed an atypical evolution of this uncommon pattern. The computed tomography scan and cerebrospinal fluid were normal. We are not aware of any other report in the literature with this atypical evolution of SREDA.

KEY WORDS: subclinical rhythmic electrographic discharge in adults (SREDA), EEG.

Descarga eletrográfica rítmica subclínica do adulto: uma evolução atípica

RESUMO - A descarga eletrográfica rítmica subclínica do adulto tem sido raramente referida na literatura. Relatamos o caso de um homem de 71 anos com ataque isquêmico transitório, cujo EEG mostrou evolução atípica deste padrão incomum. A tomografia computadorizada de crânio e o líquido cefalorraquidiano foram normais. Na literatura por nós pesquisada, não achamos outra publicação com evolução atípica do SREDA.

PALAVRAS-CHAVE: descarga eletrográfica rítmica subclínica do adulto (DERSA) (SREDA), EEG.

The subclinical rhythmic electrographic discharge in adults (SREDA)¹⁰ was first described as "décharges paroxystiques du carrefour" by Naquet et al. (1961,1965)^{6,7} and it is considered a benign EEG pattern of uncertain significance¹¹. It may closely resemble an EEG seizure pattern and it is an unusual EEG finding^{5,9,10} with an incidence of 0.02-0.045%².

Our aim in this paper is to report a case of this rare situation on EEG.

CASE REPORT

JTN, a 71-year-old man with a story of hypertension and ischemic attack was referred to the neurological emergency room. At the first neurologic examination he was conscient, disphasic and without other neurological signs. The disphasy (Wernicke's type) lasted 20h and then disappeared. ECG, echocardiography, CSF and CT scan were normal. His neurologic status remained stable, and at hospital day 2 an EEG was recorded.

The first EEG (EEG1) was performed 24 h after the onset of symptoms and lasted 45 min. The patient was resting quietly with eyes closed and exposed to minimal background noise. EEG tracings were obtained on

* Head of the EEG Sector, Escola Paulista de Medicina (EPM); **Resident in Neurology; ***Junior Doctor of the EEG Sector, **** Full Professor and Head of the Discipline of Neurology, EPM. Aceite: 14-outubro-1994.

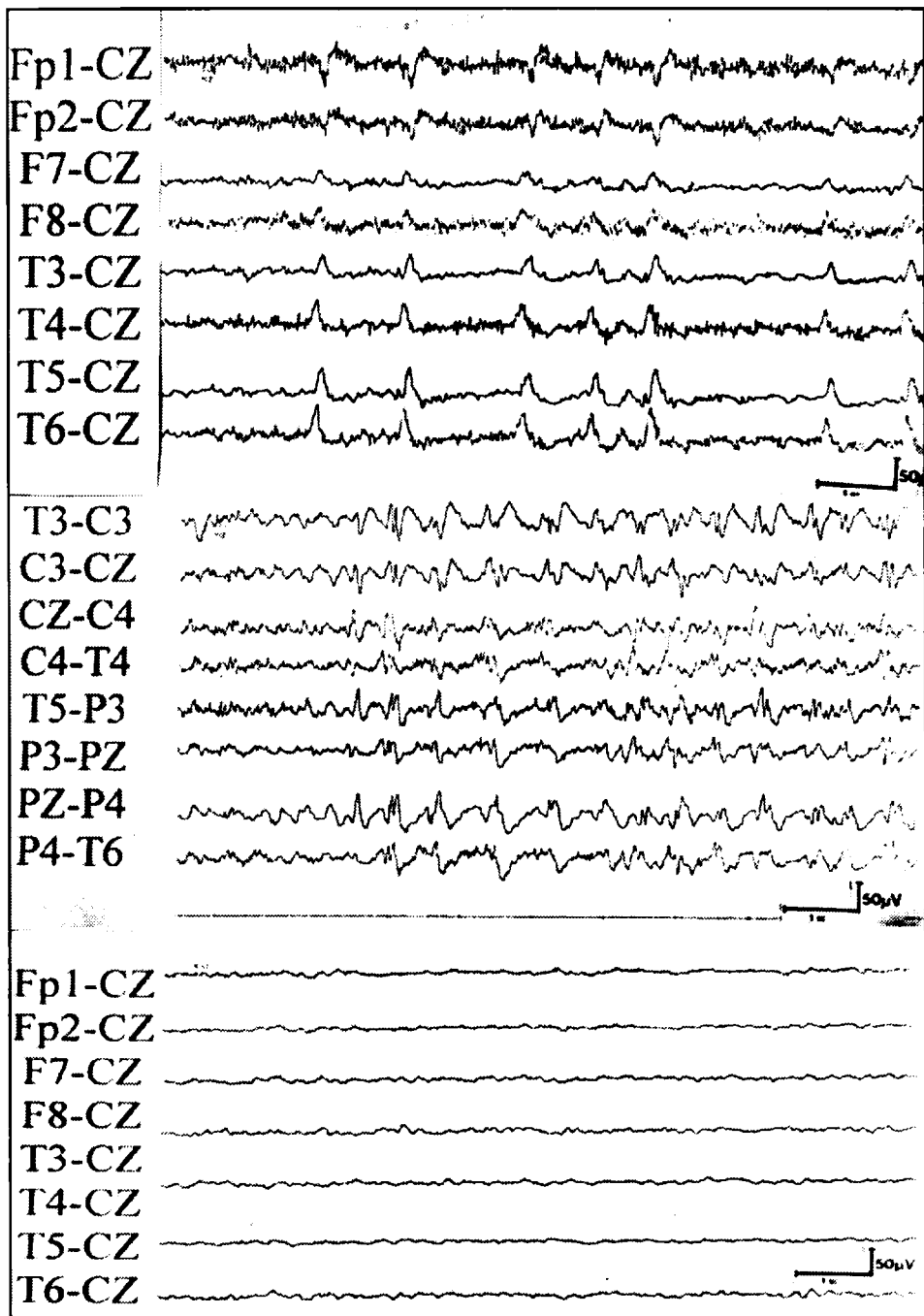


Fig 1. A generalized subclinical discharge of the Naquet-type lasted 5.2 min: a) Initially isolated sharp waves, with a posterior predominance. b) After 25 sec, rhythmic, 6 Hz waves appeared and persisted until the abrupt termination (c).

a Grass and Berger Model TP 119 -channel during the awake and asleep state. Scalp electrodes were placed according to the international 10-20 system³. The time constant was 0.3 and paper speed 30mm/s.

The EEG1 showed four discharges with the following durations: two with 5.2 and 1.2 min and the others with 40 and 50 sec. The discharges began suddenly with repetitive monophasic sharp waves (Fig1a), then increasing in frequency to a sustained rhythmic pattern of 6-8 Hz, often intermixed with sharp waves (Fig1b). The end of the discharges was usually abrupt with immediate normalization of the record (Fig1c). The discharges were generalized with bitemporal predominance. The hyperpnea and the intermittent light stimulation had no effect during the record. During the SREDA the patient had no clinical objective or subjective symptomatology and answered simple or complex questions.

Following discharge from hospital after 72h, the patient was seen monthly as an outpatient and was without symptoms. The second, third and fourth EEG were performed during each examination and were normal.

COMMENTS

Since the first report of "décharges paroxystiques du carrefour" by Naquet et al.^{6,7} there are few reports in the literature about this rare EEG pattern^{2,5,9,10}. It is also known as Naquet-type discharge² and SREDA¹⁰. It is important not to misinterpret this EEG pattern as a seizure discharge. Naquet et al.⁶ and Gastaut and Naquet¹ described the SREDA as a paroxysmal discharge, with an abrupt onset, which may last for over 1 min, progressively increases in frequency, and with a termination usually abrupt with immediate normalization of the record. It may be focal or generalized, but predominates in the region of the "carrefour" (temporo-parieto-occipital region).

In our patient the SREDA was seen only during the first EEG, but had all the characteristics described by Naquet et al.⁶. The other three EEG during the follow-up were normal and the patient was symptom-free. We are not aware of any other report in the literature with this evolution in the EEG. In the study of Westmoreland and Klass¹⁰ eleven patients that had sequential EEG the SREDA was always present. Tanarro and Lope⁸ described 15 patients with SREDA and "rhythmic midtemporal discharge"¹⁴ that disappeared in some of the EEG of four patients during the follow-up. However, it was not clear in their paper which type of EEG pattern had this evolution. Recently, the work of Thomas et al.⁹ describes a patient with a follow-up of 8 months and all the three EEG showed the SREDA.

The mechanism underlying the SREDA is not well established. The theory proposed by Naquet et al.⁶ is that it may be related to hypoxic/ischemic mechanisms in old patients. Tannarro and Lope⁸ published a study in which six patients (aged between 31 and 50 years) showed both SREDA and "rhythmic midtemporal discharge" and their observations suggest that "these two types of discharge are analogous and may even represent an identical phenomenon". Thomas et al.⁹ in a study with single photon emission computed tomography (SPECT) concluded that SREDA cannot be considered as an epileptic pattern and may be associated to vascular mechanisms. This was the probable precipitating factor of the SREDA in our case because it was a 71-year-old patient with a systemic arterial hypertension and a clinical picture of a transient ischemic attack.

SREDA is still considered a benign EEG pattern of uncertain significance, but should not be misinterpreted as an epileptic pattern.

REFERENCES

1. Gastaut H, Naquet R. Étude électroencéphalographique de l'insuffisance circulatoire cérébrale. Symposium International sur la Circulation Cérébrale. Paris: Sandoz, 1966, p 163-191.
2. Herranz F, Lope S. Subclinical paroxysmal rhythmic activity (Abstr). *Electroenceph Clin Neurophysiol* 1984, 58:5.
3. Jasper H. The ten-twenty electrode system of the International Federation. *Electroenceph Clin Neurophysiol* 1958, 10:371-375.
4. Lipman IJ, Hughes JR. Rhythmic mid-temporal discharges: an electroclinical study. *Electroenceph Clin Neurophysiol* 1969, 27:43-47.

5. Miller CR, Westmoreland BF, Klass DW. Subclinical rhythmical EEG discharges of adults (SREDA): further observations. *Am J EEG Technol* 1985, 25:217-224.
6. Naquet R, Louard C, Rhodes J, Vigouroux M. A propos de certaines décharges paroxystiques du carrefour pariéto-temporo-occipital: leur activation par l'hypoxie. *Rev Neurol* 1961, 105:203-207.
7. Naquet R, Franck G, Vigouroux M. Données nouvelles sur certaines décharges paroxystiques du carrefour pariéto-temporo-occipital, rencontrées chez l'homme. *Zbl Neurochir* 1965, 25:153-180.
8. Tanarro FJH, Lope ES. EEG subclinical paroxysmal rhythmic activity. *Rev EEG Neurophysiol* 1984, 14:9-15.
9. Thomas P, Migneco O, Darcourt J, Chatel M. Single photon emission computed tomography study of subclinical rhythmic electrographic discharge in adults. *Electroenceph Clin Neurophysiol* 1992, 83:223-227.
10. Westmoreland BF, Klass DW. A distinctive rhythmic EEG discharge of adults. *Electroenceph Clin Neurophysiol*, 1981, 51:186-191.
11. Westmoreland BF. Benign EEG variants and patterns of uncertain significance. In Daly DD, Pedley TA (eds). *Current practice of clinical EEG*. Ed 2. New York: Raven Press, 1990, p 243-252.