

Pterygium growing below the LASIK flap region

Pterígio sob flap de LASIK

Thiago Gonçalves dos Santos Martins¹, Francisco Javier Solano Moncada², Alexa Jose Escudero Sisosi³, Ana Luiza Fontes de Azevedo Costa²

ABSTRACT

Pterygium is a fibrovascular lesion of the ocular surface that can display an aggressive clinical behavior and, occasionally, threaten vision. Although there is no consensus on its pathogenesis, recent evidence suggests that it is a proliferative, rather than degenerative condition, strongly correlated with exposure to ultraviolet radiation. We report a case of pterygium that grew up below the flap Lasik region after the surgery.

Keywords: Pterygium/surgery; keratomeleusis, laser in situ; Tomography, optical coherence; Case reports

RESUMO

O pterígio é uma lesão fibrovascular da superfície ocular que pode ter um comportamento agressivo e em alguns casos ameaçar a visão. Embora não exista consenso da sua patogênese, evidências recentes sugerem que seja uma condição proliferativa relacionada com a exposição à radiação ultravioleta. Relatamos aqui um caso de pterígio que cresceu sob a região do flap de cirurgia refrativa (LASIK).

Descritores: Pterígio/cirurgia; Ceratomeleuse assistida por eximer laser in situ; Tomografia de coerência ótica; Relatos de casos

¹ Universidade Federal de São Paulo, Escola Paulista de Medicina, São Paulo, SP, Brazil.

² Universidade de São Paulo, São Paulo, SP, Brazil.

³ Charing Cross Hospital, Imperial College, London.

The authors declare no conflicts of interests.

Received for publication 08/01/2015 - Accepted for publication 01/09/2015

INTRODUCTION

Pterygium has been related to ocular exposure to ultraviolet radiation, which can lead to the growth of a fibrovascular proliferation on the cornea.⁽¹⁾ It is usually more prevalent in regions near the equator, affecting 22% of the population in these areas.⁽²⁾ The trauma caused by refractive surgery releases growth factors that can encourage the emergence of pterygium.

CASE REPORT

Male patient, 42 years, complaining of ocular hyperemia and foreign body sensation in the right eye for 5 days. Reported refractive surgery (LASIK) 5 years before. Ophthalmological examination showed nasal pterygium growth under the flap region, and vision of 20/20 with correction in both eyes. The optical coherence tomography of the cornea was carried out to the patient to confirm the diagnosis (Figure 1). We opted for watchful waiting, just following the development of the patient.

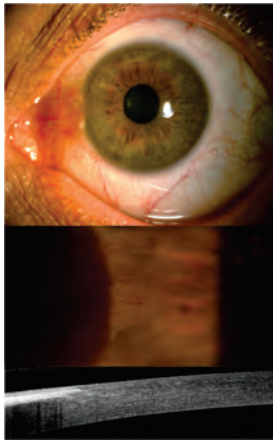


Figure 1: Nasal pterygium growing under the LASIK flap region, showed by the exam of optical coherence tomography - Visante.

DISCUSSION

The excimer laser may precipitate the release of cytokines and growth factors present in the patient's cornea, which can lead to the development of the pterygium.⁽³⁾ These factors were also observed by Di Girolamo et al.⁽⁴⁾ This case shows that the inflammation caused by the refractive surgery can be another stimulating factor for the rise of pterygium. The laser leads to a process of cell necrosis in the corneal stroma around the lamella cut, which generates the release of lysosomal enzymes from intracellular components and an attraction of a greater number of inflammatory cells into the region.⁽⁵⁾

Pterygium is classically defined as a degenerative disease of the ocular surface with fibrovascular tissue formation of triangular shape, which grows from the conjunctiva onto the cornea.⁽¹⁾ Although its pathogenesis has not been completely clarified, it is very likely that pterygium represents a degenerative response of the fiber from the fibrous connective tissue to different stimuli. Among the risk factors, the exposure to ultraviolet radiation seems to play an important role for inducing damage to the limbic germ cells. As consequences, there are conjunctival migration towards the cornea, chronic inflammation,

and formation of fibrovascular tissue⁽²⁾. Other risk factors described related to the development of pterygium are the micro-injuries in the limbo and the hereditary factors.^(3, 4, 6)

Frequently, pterygium originates chronic irritative symptoms as foreign body sensation, burning, ocular hyperemia or photophobia. With the progression, it can be extended over the cornea, decreasing the visual acuity by astigmatism induced by obstructing the passage of light when it is facing the visual axis or due to changes in the refractive surface determined by changes in the tear film.⁽⁶⁾

Several surgical procedures have been proposed for the treatment of pterygium, all with the common purpose of performing excision and preventing reoccurrence. However, various complications related to adjuvants techniques and treatments have been reported⁽⁷⁻⁹⁾. The recurrence of pterygium after its removal is the most common cause of surgical failure. Recurrence generates the formation of dense fibrovascular tissue, conjunctival inflammation, and pronounced corneal impairment.^(10, 11)

The patient had nasal pterygium not causing the decrease of visual acuity. Thus, watchful waiting was chosen.

REFERENCES

- Hilgers J. Pterygium: its incidence, heredity and etiology. *Am J Ophthalmol.* 1960; 50:635-44.
- Coreneo MT. Pterygium as an early indicator of ultraviolet insolation: a hypothesis. *Br J Ophthalmol.* 1993; 77(11):734-9.
- Baldwin HC, Marshal J. Growth factors in corneal wound healing following refractive surgery: a review. *Acta Ophthalmol Scand.* 2002; 80(3):238-47.
- Di Girolamo N, Chui J, Coreneo MT, Wakefield D. Pathogenesis of pterygia: role of cytokines, growth factors, and matrix metalloproteinases. *Prog Retin Eye Res.* 2004;23(2):195-228. Review.
- Santhiago MR, Wilson SE. Cellular effects after laser in situ keratomileusis flap formation with femtosecond lasers: a review. *Cornea.* 2012;31(2):198-205.
- Oldenburg JB, Garbus J, McDonnell JM, McDonnell PJ. Conjunctival pterygia. Mechanism of corneal topographic changes. *Cornea.* 1990;9(3):200-4.
- Tan DT, Chee SP, Dear KB, Lim AS. Effect of pterygium morphology on pterygium recurrence in a controlled trial comparing conjunctival autografting with bare sclera excision. *Arch Ophthalmol.* 1997;115(10):1235-40. Erratum in: *Arch Ophthalmol.* 1998;116(4):552.
- Prabhasawat P, Barton K, Burkett G, Tseng SC. Comparison of conjunctival autografts, amniotic membrane grafts, and primary closure for pterygium excision. *Ophthalmology.* 1997;104(6):974-8.
- Chen PP, Ariyasu RG, Kaza V, LaBree LD, McDonnell PJ. A randomized trial comparing mitomycin C and conjunctival autograft after excision of primary pterygium. *Am J Ophthalmol.* 1995;120(2):151-60.
- Mackenzie FD, Hirst LW, Battistutta D, Green A. Risk analysis in the development of pterygia. *Ophthalmology.* 1992;99(7):1056-61.
- Tan DT, Liu YP, Sun L. Flow cytometry measurements of DNA content in primary and recurrent pterygia. *Invest Ophthalmol Vis Sci.* 2000;41(7):1684-6.

Corresponding author:

Thiago Gonçalves dos Santos Martins
Rua Botucatu, 821 - Vila Clementino, São Paulo
Postal ZIP Code: 04023-062
Tel.: 552125712248
E-mail: thiagogsmartins@yahoo.com.br